

Clinico-pathologic Appraisal of Lipomatous Lesions in the Head and Neck Region; a Multicenter Nigerian Study

Ramat Oyeibunmi Braimah^{1*}, Olujide Oladele Soyele², Abdulrazaq Olanrewaju Taiwo³,
Adebayo Aremu Ibikunle¹, Micah Olalekan Gbotolorun⁴

1. Department of Dental and Maxillofacial Surgery, Usmanu Danfodiyo University Teaching Hospital, Sokoto, Nigeria.

2. Department of Oral & Maxillofacial Surgery and Oral Pathology, Obafemi Awolowo University Teaching Hospital Ile-Ife, Osun State, Nigeria.

3. Department of Surgery, College of Health Sciences, Usmanu Danfodiyo University Sokoto, Nigeria.

4. Department of Oral and Maxillofacial Surgery, College of Medicine, University of Lagos. Nigeria.

Submitted 15 Apr 2017; Accepted 3 May 2017; Published 13 Jun 2017

Lipomatous tumors originate from adipocytes, and represent the largest group of mesenchymal tumors. Lipomas are most likely under reported due to their insidious growth. About 13% of lipomas occur in the head and neck region. When they occur in the maxillofacial region, it is likely for the patients to be referred to the hospital for aesthetical reasons. In this multicenter study, data such as age, sex, duration of lesion, widest diameter of lesion and histological diagnosis was extracted from three university teaching hospitals in Nigeria. 50 cases of lipomatous tumours were seen during the study period. There were 30 males and 20 females. Age ranged between 2 months and 62 years. 14 cases (28%) were seen in the age group of 41-50 years. There was no statistical difference between age, sex and duration of lesion ($P=0.995$, 0.183 and 0.482 , respectively). There were 48 cases of benign lipomatous tumors and 2 cases of malignant types with a statistical significant difference ($P<0.001$). Most of the lesions (23 cases (46.0%)) were located in the cheek. As most of lipomatous lesions in the head and neck region are benign neoplasm with low prevalence in the oral cavity, health care providers must be able to diagnose the lesion and manage them appropriately.

Keywords: Adipocytes, head and neck, lipomatous lesions, mesenchymal tumors

Lipomatous tumors originate from adipocytes, and are the most common mesenchymal and soft tissue neoplasm in humans (1). Lipomas or liposarcomas represent the majority of fatty tumors. They may occur at every age, but are commonly encountered in adults aged from 40 to 60 years, although they can also be found in younger adults and children (2).

Because most cases of lipomas grow insidiously and cause few symptoms except that of a

localized mass, it has attracted relatively little interest in the literature (1). The number of reported cases of lipomas is most likely lower than the actual incidence because it is discovered insidiously, and is often not recorded. Furthermore, they rarely cause cosmetic problem or interfere with body function because of their anatomic location (3). However, when they occur in the head and neck region, there is a likelihood of early presentation, especially in the maxillofacial region. Among adipocyte benign

*Correspondence: Braimah Ramat Oyeibunmi: Department of Dental and Maxillofacial Surgery, Usmanu Danfodio University Teaching Hospital, Sokoto, Sokoto State, Nigeria. E-mail: robdeji@yahoo.com

tumors, more than 80% are lipomas and about 13% occur in the head and neck region, especially in the posterior neck (4). The aim of this study was to investigate the characteristics of head and neck lipomatous tumors diagnosed in health care centers in Nigeria.

Materials and methods

This was a retrospective study of cases of histologically diagnosed head and neck lipomatous tumors from three tertiary health care facilities in Nigeria. Data such as age, sex, duration of lesion, widest diameter of lesion and histological diagnosis was extracted and analyzed using IBM SPSS Statistics for windows Version 20 (Armonk, NY: IBM Corp). Results were presented as simple frequencies and descriptive statistics. $P < 0.05$ was considered as statistically significant.

Results

Fifty cases of lipomatous tumors were collected. They belonged to 30 males and 20 females. Their age ranged between 2 months and 62 years. Fourteen cases (28%) were seen in the 41-50 years age group (Table 1).

The duration of lesion before presentation in the hospital ranged from birth to 17 years with highest cases (21 (42.0%)) presenting between 1-5 years of onset of swelling (Table 2). There was no statistical difference between age, sex and duration of lesion ($P = 0.995, 0.183$ and 0.482 , respectively). There were 48 cases of benign lipomatous tumors and 2 cases of malignant types (Table 3) with a statistical significant difference ($P < 0.001$). Most of the lesions (23 cases (46.0%)) were located in the cheek (Figure 1).

Table 1. Distribution of age group of patients presenting with lipomatous lesions

Age (years)	Freq	%
< 1	2	4.0
1-10	7	14.0
11-20	2	4.0
21-30	7	14.0
31-40	13	26.0
41-50	14	28.0
51-60	3	6.0
61-70	2	4.0
Total	50	100.0

Table 2. Distribution of symptom duration before hospital presentation

Duration (years)	Freq	%
< 1	18	36.0
1-5	21	42.0
6-10	8	16.0
11-15	1	2.0
16-20	1	2.0
21-25	-	-
36-40	-	-
41-45	1	2.0
Total	50	100.0

Table 3. Distribution of benign and malignant lipomatous lesions

	Frequency	%
Benign		
lipoma	23	46.0
Fibrolipoma	17	34.0
Lipofibroma	7	14.0
Myxofibrolipoma	1	2.0
Malignant		
Myxoliposarcoma	1	2.0
Round cell liposarcoma	1	2.0

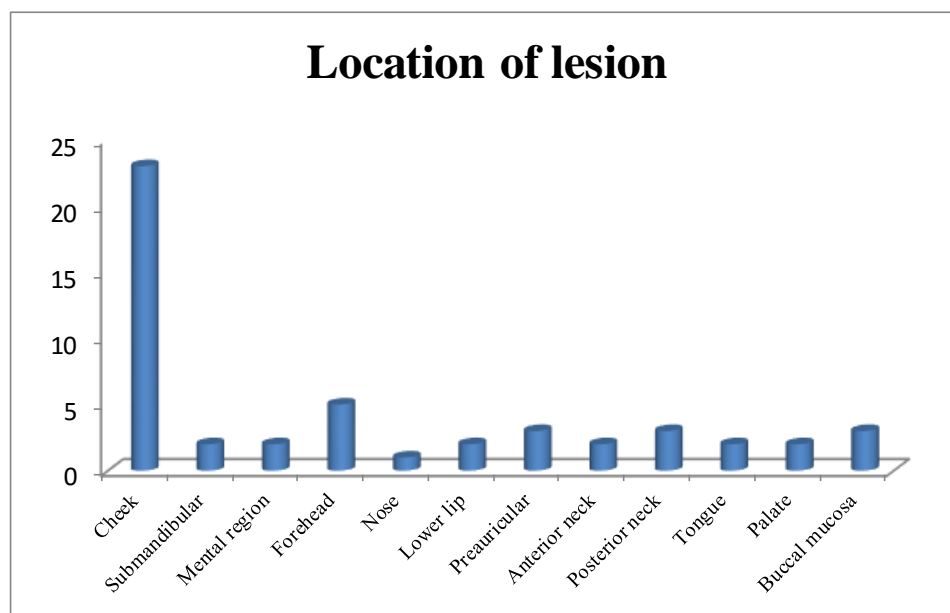


Figure 1. Distribution of location in patients presenting with head and neck lipomatous lesions.

Discussion

Lipomatous tumors are adipocytic tumors that represent the largest single group of mesenchymal tumors because of the high prevalence of lipomas and angiolipomas (5). They are the most commonly encountered mesenchymal and soft tissue neoplasm in humans. Lipomas are usually composed of mature fat and are capsulated (6). Most are subcutaneous and superficial in position. The etiology of lipomas is still obscure although thought to be due to repeated trauma that can trigger the proliferation of fatty tissue leading to lipoma (7). Some other studies have identified endocrine and inflammatory influences as possible etiological factors (8).

Lipomatous lesions are said to be rare in the first two decades of life and usually just beginning in the fifth and sixth decades when fat begins to accumulate (3). Findings in the present study have supported this position, as most of the cases (26% and 28%) were seen in the fourth and fifth decade, respectively. Contrary to previously reported female preponderance (9), the present study showed a male preponderance of ratio 1.5:1. Similar male preponderance has been reported by de Visscher (7). The reason for this male preponderance remains obscure. However, Manor et al. have reported no sex predilection (10).

Literature search did not report on duration of

lesion before presentation in the hospital, however, Okada et al. in Japanese population have reported an average duration of 36 months in liposarcomas of the extremities (11). In the present study, most of the patients (78%) presented within 60 months of the onset of the lesion.

Lipomas are usually seen in the trunk, extremities and head and neck region, but rarely intra-orally (12). Intraoral lipomas represent about 1% to 4% of all benign tumors involved in oral cavity (13, 14). When seen intraorally, the buccal mucosa is the commonest site, perchance because of the comparative availability of adipose tissue at this location (15, 16). The present study has corroborated this position as most of the lipomas (46.0%) were seen in the cheek/buccal mucosa.

The majority of fatty tumors are either lipomas or liposarcomas and occur at every age and at almost any anatomical location. In the literature, most of the lipomatous lesions are lipomas (5) and the present study is in tandem with the literature as 46% of cases seen were lipomas, 34% fibrolipomas and 14% lipofibromas. Only one case of myxofibrolipoma was seen in our series. Myxofibrolipoma is a distinctive benign soft tissue neoplasm that may be mistaken for a sarcoma (17). The tumor represents the collective features of spindle cell lipoma and solitary fibrous tumor (17). Head and neck regions are the most common sites for myxofibrolipomas, followed by the chest and the back (18).

It has been reported that malignant transformation of lipomas into liposarcomas is a very rare occurrence as most cases arise de novo (19). However, lipomas in bone and the kidneys have been reported to undergo malignant transformation (20, 21). Goldblum et al. suggested that few reported cases of malignant transformation may be cases of well-differentiated liposarcomas in which the subtle malignant characteristics were missed when the tumor was first evaluated (22). We reported only 2 (4.0%) cases of liposarcoma (myxoliposarcoma and round cell liposarcoma). The most recent world health

organization classification of soft tissue tumors has classified liposarcomas into 5 subtypes: (1) well differentiated, which includes the adipocytic, sclerosing, and inflammatory subtypes; (2) dedifferentiated; (3) myxoid; (4) round cell; and (5) pleomorphic (5). Liposarcoma is the most common soft tissue sarcoma, accounting for approximately 17% of all soft tissue sarcomas and 3% of all liposarcomas in the head and neck region (usually the neck and the cheek). Relatively, they are involved in only 4% of childhood soft tissue sarcomas. Cases of liposarcoma are usually seen in young adults and teenagers, but mean patient age at onset is reported to be 50 years (23). The two cases seen in the present study were aged 50 and 45 years which agrees with the age reported in the literature. Finally, most of lipomatous lesions in the head and neck region are benign neoplasm with low prevalence in the oral cavity. Health care providers must be able to diagnose the lesion and right treatment should be carried out to ensure patients comfort, welfare and to improve life quality.

Conflict of interest

The authors declared no conflict of interest.

References

1. Bancroft L W, Kransdorf M J, Peterson J J, et al. Benign fatty tumors: classification, clinical course, imaging appearance, and treatment. *Skeletal Radiol.* 2006;35:719-33.
2. Salam G A. Lipoma excision. *Am Fam Physician.* 2002;65:901-4.
3. Som P M, Scherl M P, Rao V M, et al. Rare presentations of ordinary lipomas of the head and neck: a review. *AJNR Am J Neuroradiol.* 1986;7:657-64.
4. Barnes L. *Surgical pathology of the head and neck.* New York: Dekker; 1985.
5. Fletcher C D M, Organization W H. International Agency for Research on Cancer. *WHO classification of tumours of soft tissue and bone.* 4 ed. Lyon: IARC Press; 2013.
6. Noro Filho G A, Caputo B V, Santos C C D. Diagnosis and treatment of intraoral lipoma: a case report. *J Health Sci Inst.* 2010;28:129-31.
7. de Visscher J G. Lipomas and fibrolipomas of the oral cavity.

- J Maxillofac Surg. 1982;10:177-81.
8. Aust MC, Spies M, Kall S, et al. Lipomas after blunt soft tissue trauma: are they real? Analysis of 31 cases. Br J Dermatol. 2007;157:92-9.
9. de Freitas M A, Freitas V S, de Lima A A, et al. Intraoral lipomas: a study of 26 cases in a Brazilian population. Quintessence Int. 2009;40:79-85.
10. Manor E, Sion-Vardy N, Joshua B Z, et al. Oral lipoma: analysis of 58 new cases and review of the literature. Ann Diagn Pathol. 2011;15:257-61.
11. Okada K, Hasegawa T, Kawai A, et al. Primary (de novo) dedifferentiated liposarcoma in the extremities: a multi-institution Tohoku Musculoskeletal Tumor Society study of 18 cases in northern Japan. Jpn J Clin Oncol. 2011;41:1094-100.
12. Tettamanti L, Azzi L, Croveri F, et al. Oral lipoma: Many features of a rare oral benign neoplasm. Head Neck Oncol. 2014;10:21.
13. Gnepp D R. Diagnostic surgical pathology of the head and neck. 2 ed. Philadelphia: Saunders; 2009.
14. Weiss S W, Goldblum J R. Benign lipomatous tumors. In: Weiss SW, Goldblum JR, Enzinger FM, editors. Enzinger and Weiss's soft tissue tumors. Louis: Mosby; 2001. p. 571-639.
15. Kumar L K, Kurien N M, Raghavan V B, et al. Intraoral lipoma: a case report. Case Rep Med. 2014;2014:480130.
16. Bakshi S S, Priya M, Coumare V N, et al. A common tumor in an uncommon location: Lipoma of the palate. Ann Maxillofac Surg. 2015;5:237-9.
17. Suster S, Fisher C, Moran C A. Dendritic fibromyxolipoma: clinicopathologic study of a distinctive benign soft tissue lesion that may be mistaken for a sarcoma. Ann Diagn Pathol. 1998;2:111-20.
18. Kim S N, Kwon K H, Suh Y L. Dendritic Myxofibrolipoma. 2001;35:447-50.
19. Dalal K M, Antonescu C R, Singer S. Diagnosis and management of lipomatous tumors. J Surg Oncol. 2008;97:298-313.
20. Milgram J W. Malignant transformation in bone lipomas. Skeletal Radiol. 1990;19:347-52.
21. Lowe B A, Brewer J, Houghton D C, et al. Malignant transformation of angiomylipoma. J Urol. 1992;147:1356-8.
22. Goldblum J R, Weiss S W, Enzinger F M. Benign lipomatous tumors. 5 ed. Philadelphia: Mosby: Elsevier; 2008.
23. Vocks E, Worret W I, Burgdorf W H. Myxoid liposarcoma in a 12-year-old girl. Pediatr Dermatol. 2000;17:129-32.