

Clinico-Pathologic Review of Salivary Glands Neoplasms in a Nigerian University Teaching Hospital: A Five Year Retrospective Survey

Ramat Braimah^{1*}, Abdurrazaq Taiwo¹, Adebayo Ibikunle¹, Saddiku Sahabi²

1. Department of Dental and Maxillofacial Surgery, Usmanu Danfodiyo University Teaching Hospital, Sokoto, Nigeria.

2. Department of Morbid Anatomy and Histopathology, Faculty of Basic Medical sciences, College of Health Sciences, Usmanu Danfodiyo University, Sokoto, Nigeria.

Submitted 25 Apr 2018; Accepted 12 Jun 2018; Published 18 Jul 2018

Salivary gland neoplasms account for 0.5-2% of all tumors worldwide, and can display a remarkable range of morphological diversity between different tumor types. The aim of this retrospective study was to present the clinico-pathologic characteristics of salivary gland neoplasms in a tertiary referral hospital in northwest region of Nigeria. Clinical and histopathological records of patients with salivary gland lesions that presented to the department of Dental and Maxillofacial Surgery only, Usmanu Danfodiyo University Teaching Hospital Sokoto, between January 2013 and December 2017, was evaluated. Data concerning age, gender, location and type of salivary gland lesion, and histologic subtypes were collected. A total of 76 cases of salivary gland neoplasms were retrieved and analyzed. There were 35 (46.1%) males and 41 (53.9%) females with M: F of 1.2:1. Mean±SD age of 31.04±18.9, and range 1-73 years was observed. 53 (69.7%) cases were benign while 23 (30.3%) were malignant. Most of the benign and malignant cases were seen in the 4th decade of life. 23 (30.3%) lesions were seen in the parotid gland with 18 (23.7%) benign and 5 (6.6%) malignant. In the minor salivary glands, 15 (19.7%) lesions were observed in the palate with 4 (5.3%) benign and 11 (14.5%) malignant. Of the benign cases, pleomorphic adenoma was the most frequent 41 (53.9%) while mucoepidermoid carcinoma was the most occurring malignant case (12 (15.8%)). A distribution ratio of 1.9:1.3:1:2.2 for parotid, submandibular, sublingual, and minor salivary gland neoplasms was encountered. The peak incidences of benign and malignant tumors were in the 4th decade, which is different from Caucasians.

Keywords: Salivary gland, mucoepidermoid carcinoma, neoplasms, pleomorphic adenoma

Salivary glands are located in the head and neck region and are exocrine organs responsible for the production and secretion of saliva. They encompass the three paired major glands, the parotid, submandibular and sublingual, and the minor glands (1-2). The minor salivary glands are abundant, and are generally distributed throughout the mouth, oropharynx, upper respiratory, sinonasal tracts, and the paranasal sinuses (2). The saliva

functions as a lubricant for speech and swallowing, assists taste, has antibacterial and immunologic properties, and contains digestive enzymes (1, 3).

Salivary gland neoplasms (SGN) can display a remarkable range of morphological diversity between different tumor types, and sometimes within an individual tumor mass (4-5). In addition, hybrid tumors, de-differentiation, and the tendency for some benign tumors to progress to malignancy

*Correspondence: Department of Dental and Maxillofacial Surgery, Usmanu Danfodiyo University Teaching Hospital, Sokoto, Nigeria.
E-mail: robdeji@yahoo.com

can confuse histopathological interpretation, and make diagnosis complicated (4-5). It is difficult to know the actual overall incidence of SGN as most of the benign tumors go unrecorded in most national cancer registries (6). However, geographical variations in the incidence of these SGN have been reported (7). Literature search has shown that SGN accounts for 0.5-2% of all tumors worldwide (8). In western countries, SGN have been reported to be between 3-6% of all head and neck tumors, while in Africa it ranges between 2.8-10% (9).

Sixty-five – 70 % of SGN are reported to be benign and within the parotid gland, while in the submandibular glands about half are benign. In the Sublingual gland, tumors are very uncommon, and if present are most likely to be malignant (10). The aim of the present study was to present the clinico-pathologic features of salivary gland neoplasms in a tertiary referral hospital in northwest region of Nigeria.

Materials and methods

Patients

This was a retrospective study of clinical and histopathological records of patients with salivary gland neoplasms that presented to the department of Dental and Maxillofacial Surgery only, Usmanu Danfodiyo University Teaching Hospital Sokoto, between January 2013 and December 2017. Patients data were collected for socio-demographics (age, gender), location of salivary gland lesion, and type of salivary gland lesion, diagnosis /histologic subtypes. Those with incomplete clinical and histological records were excluded from the study. Salivary gland neoplasms were classified according to the WHO 2005 classification of salivary gland neoplasms (11).

Statistical analysis

Data was analyzed using SPSS version 20.0 (Armonk, NY: IBM Corp). Results were presented as simple frequencies and descriptive statistics. A P

value of less than 0.05 was considered significant.

Results

A total of 76 cases of SGN with complete record was retrieved, and analyzed. There were 35 (46.1%) males and 41 (53.9%) females with a M: F ratio of 1.2. Mean±SD age was 31.04±18.9 years, ranging from 1 to 73 years. There was no significant difference when age group of patients were compared with the gender ($\chi^2 = 7.511$, $df = 7$, $P = 0.378$) (Table 1). Fifty-three (69.7%) cases were benign while 23 (30.3%) were malignant. Most of the benign and malignant cases were seen in the age group 31-40 years (16 (20.1%) benign and 8 (10.5%) malignant) (Figure 1). The peak age for benign and malignant case in the current study was in the 4th decade of life (Table 2).

In the major salivary glands, 23 (30.3%) lesions were seen in the parotid gland with 18 (23.7%) benign cases and 5 (6.6%) malignant, while in the minor salivary glands, 15 (19.7%) lesions were observed in the palate (4 (5.3%) benign and 11 (14.5%) malignant) with statistical significance of $P < 0.001$. Table 3 shows the distribution of type and site of salivary gland neoplasms. Only 1 (1.3%) case of malignancy was seen in the submandibular gland. No malignant tumor was observed from our series in the sublingual gland as simple (10 (13.2%)) and plunging (2 (2.6%)) ranula were the only lesions associated with it. Distribution of diagnosis and site of salivary gland neoplasms is shown in Table 4. Of the benign cases, pleomorphic adenoma was the most frequent (41 (53.9%)) while plunging ranula was the least frequent (4 (5.3%)). Mucoepidermoid carcinoma was the most occurring malignant case (12 (15.8%)) (low grade 9 (11.8%), intermediate grade 1 (1.3%), high grade 2 (2.6%)), while carcinoma-in-pleomorphic adenoma was the least (2 (2.6%)) (Table 5).

Table 1. Distribution of age group and gender of patients with salivary gland neoplasms

Age group (years)	Male (%)	Female (%)	Total (%)
1-10	9 (11.8)	4 (5.3)	13 (17.1)
11-20	5 (6.5)	5 (6.6)	10 (13.1)
21-30	6 (7.9)	6 (7.9)	12 (15.8)
31-40	10 (13.2)	14 (18.4)	24 (31.6)
41-50	1 (1.3)	3 (3.9)	4 (5.2)
51-60	2 (2.6)	7 (9.2)	9 (11.8)
61-70	2 (2.6)	1 (1.3)	3 (3.9)
71-80	1 (1.3)	0 (0.0)	1 (1.3)
Total	36 (47.4)	40 (52.6)	76 (100.0)

$\chi^2 = 7.511$, $df = 7$, $P = 0.378$.

Table 2. Distribution of type and age range of salivary gland neoplasms

Age range	Benign (%)	Malignant (%)	Total (%)
1-10	13 (17.1)	0 (0.0)	13 (17.1)
11-20	6 (7.9)	4 (5.3)	10 (13.2)
21-30	9 (11.8)	3 (4.0)	12 (15.8)
31-40	16 (21.1)	8 (10.5)	24 (31.6)
41-50	1 (1.3)	3 (4.0)	4 (5.3)
51-60	7 (9.2)	2 (2.6)	9 (11.8)
61-70	1 (1.3)	2 (2.6)	3 (3.9)
71-80	0 (0.0)	1 (1.3)	1 (1.3)
Total	53 (69.7)	23 (30.3)	76 (100.0)

$\chi^2 = 14.613$, $df = 7$, $P = 0.041$.

Table 3. Distribution of type and site of salivary gland neoplasms

Site	Benign (%)	Malignant (%)	Total (%)
MAJOR			
Parotid	18 (23.7)	5 (6.6)	23 (30.3)
Submandibular	14 (18.4)	1 (1.3)	15 (19.7)
Sublingual	12 (15.8)	0 (0.0)	12 (15.8)
Total	44 (57.9)	6 (7.8)	50 (65.7)
MINOR			
Palate	4 (5.3)	11 (14.5)	15 (19.7)
Lower lip	1 (1.3)	0 (0.0)	1 (1.3)
Buccal sulcus	3 (3.9)	3 (3.9)	6 (7.8)
Labial sulcus	0 (0.0)	1 (1.3)	1 (1.3)
Cheek	1 (1.3)	0 (0.0)	1 (1.3)
Maxillary sinus	0 (0.0)	2 (2.6)	2 (2.6)
Total	9 (11.8)	17 (22.4)	26 (34.2)
Grand total	53 (69.7)	23 (30.3)	76 (100.0)

$\chi^2 = 32.030$, $df = 8$, $P < 0.001$.

Table 4. Distribution of diagnosis and site of salivary gland neoplasms

Diagnosis	PARG	SMG	SLG	MP	MS	MO	Total
PA	18 (23.7)	14 (18.5)	0 (0.0)	4 (5.3)	0 (0.0)	5 (6.6)	41 (54.0)
RAN	0 (0.0)	0 (0.0)	10 (13.2)	0 (0.0)	0 (0.0)	0 (0.0)	10 (13.2)
PLUNG RAN	0 (0.0)	0 (0.0)	2 (2.6)	0 (0.0)	0 (0.0)	0 (0.0)	2 (2.6)
ADCCA	0 (0.0)	0 (0.0)	0 (0.0)	5 (6.6)	0 (0.0)	1 (1.3)	6 (7.9)
MUEDCA	3 (3.9)	1 (1.3)	0 (0.0)	4 (5.3)	2 (2.6)	2 (2.6)	12 (15.8)
PMLGADCA	1 (1.3)	0 (0.0)	0 (0.0)	1 (1.3)	0 (0.0)	1 (1.3)	3 (3.9)
CAEXPA	1 (1.3)	0 (0.0)	0 (0.0)	1 (1.3)	0 (0.0)	0 (0.0)	2 (2.6)
Total	23 (30.3)	15 (19.8)	12 (15.8)	15 (19.8)	2 (2.6)	9 (11.8)	76 (100.0)

PA: pleomorphic adenoma; RAN: ranula; PLUNG RAN: plunging ranula; ADCCA: adenocystic carcinoma; MUEDCA: mucoepidermoid carcinoma; PMLGADCA: polymorphous low grade adenocarcinoma; CAEXPA: carcinoma ex pleomorphpic adenoma; PARG: parotid gland; SMG: submandibular gland; SLG: sublingual gland; MP: minor palatal; MS: minor sinus; MO: minor others. $\chi^2=178.568$, $df = 80$, $P < 0.001$.

Table 5. Distribution of salivary gland neoplasms diagnosis

Diagnosis	Number	%
BENIGN		
Pleomorphic adenoma	41	53.9
Plunging ranula	2	2.6
Ranula	10	13.2
Total Benign	53	69.7
MALIGNANT		
Adenocystic carcinoma	6	7.9
Polymorphous low grade adenocystic carcinoma	3	3.9
High grade mucoepidermoid carcinoma	2	2.6
Intermediate grade mucoepidermoid carcinoma	1	1.3
Low grade mucoepidermoid carcinoma	9	11.8
Carcinoma in pleomorphic adenoma	2	2.6
Total Malignant	23	30.3
Total Benign and Malignant	76	100.0

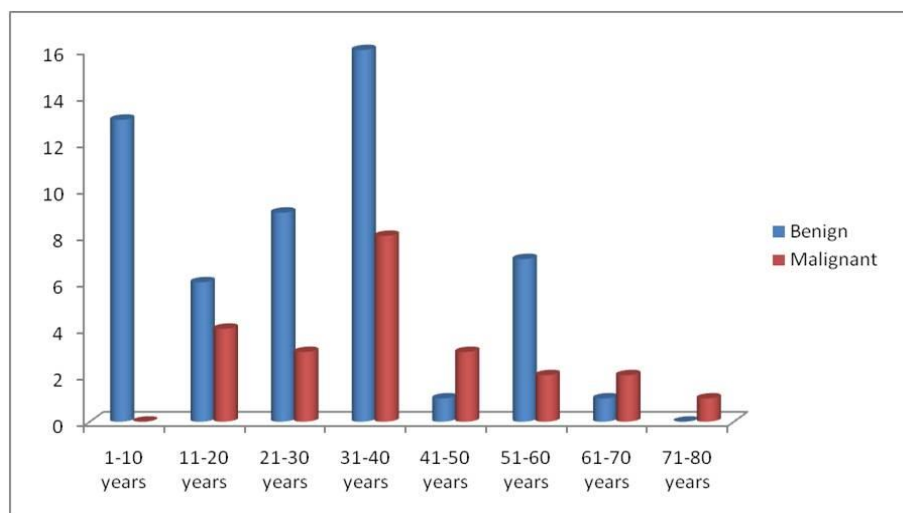


Figure 1. Age group distribution of benign and malignant cases.

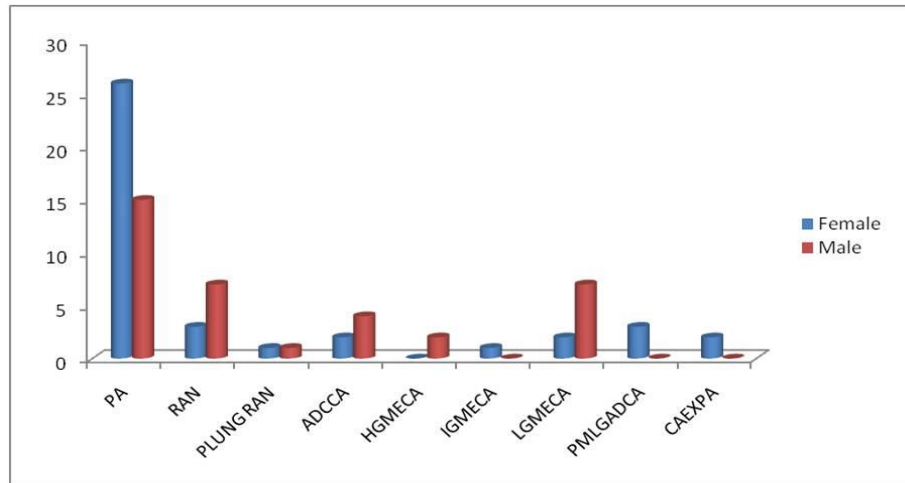


Figure 2. Gender distribution of salivary gland lesions. PA: pleomorphic adenoma; RAN: ranula; PLUNG RAN: plunging ranula; ADCCA: adenocystic carcinoma; HGMECA: high grade mucoepidermoid carcinoma; IGMECA: intermediate grade mucoepidermoid carcinoma; LGMECA: low grade mucoepidermoid carcinoma; PMLGADCA: polymorphous low grade adenocarcinoma; CAEXPA: carcinoma ex pleomorphic adenoma.

Discussion

Because of the diverse nature of SGN, many different classification systems have been developed, however none has been able to satisfy all clinicians managing these disease conditions (4). The most recent 2005 WHO classification of SGN has been considered the yardstick for reporting and pathological classification of these diverse group of tumors (11). African studies have documented age range of SGN to be between 1-70 years with peak age in the 3rd and 4th decade (7, 12). This present study has find out similar data as age range of 1-70 years with peak presentation in the 3rd and 4th decades of life. Similar findings have also been reported in a sister department of the same institution (13). The peak age for benign SGN in the current study was in the 4th decade of life, this is similar to the findings from studies in Ibadan (Nigeria) (14) and South Africa (15). However, this contrasts other studies where a peak age of benign SGN was reported to be in 3rd decade of life (16-18).

It is surprising to note that the present study observed peak age of malignant SGN to be in the 4th decade of life. Reports have shown these lesions to be common in the 7th-8th decades of life among Caucasians (11). However, in African and Asian studies, a peak age of 5th -6th decade has been

documented (7, 14, 15, 19). A decade lower than that reported in African studies may signal higher prevalence of malignant neoplasms in African populations. Taiwo et al. have reported a higher incidence of malignant neoplasms in children and adolescents' from the same centre (20).

Female gender predilection of the current study (Figure 2) is in tandem with reported cases of SGN (19, 21-25). On the contrary, male gender predilection has been reported in other studies (13, 17, 26-27). The reason for male preponderance has been attributed to male societal dominance in northern part of Nigeria and some African countries (13). Although, this current study was conducted in extreme North West region of Nigeria, female preponderance was still observed. We opined that good health seeking behaviour of the female folks could be responsible despite the male dominant status of the region. Equal gender predilection has however been reported in other studies (14, 18, 28-29).

Generally, salivary glands are classified as either major or minor and tumors arising from them can also be classified as such (27). The major SGN originate from the parotid, submandibular or the sublingual glands, while the minor SGN originates from minor glands scattered in the oral/nasal

cavities. Globally, SGN distribution according to site has followed the rule of 1:0.1:0.01:0.1 for parotid, submandibular, sublingual, and minor salivary glands (13), however several other distributions has been reported from different studies. Oti et al. (30), Jude et al. (7), and Aliyu et al. (13) has reported 3:2:0:1, 3.5:1:0:1.5, and 3:2:0.44:7 ratio, respectively. Site distribution from the current study was 1.9:1.3:1:2.2. Clearly from all reported distributions and the current study, it has been shown that parotid gland has the highest distribution while sublingual gland has the least distribution. In the white population in Europe and America, more proportion of tumors occur in the parotid while in African population more neoplasms occur in the minor salivary glands (23). This study has reaffirmed this position as the minor salivary glands have more neoplasms compared with the parotid. This further suggests racial variation in the clinico-pathologic distribution of SGN worldwide.

Of the major SGN, parotid gland has been reported to have higher incidence with majority of them being benign tumors (27, 29, 31-32). This report has been corroborated by the current study as most of the tumors were seen in the parotid gland (23 (30.3%)) with mostly benign tumors (18 (23.7%)). However, Aliyu et al. (13) have reported more of malignant lesion in the parotid gland. Of the benign tumors within the parotid, pleomorphic adenomas has been documented to be more commonly found (31). This is in tandem with the current study as most of the benign parotid gland tumors were pleomorphic adenoma. Only ranula (simple 10 (13.2%) and plunging 2 (2.6%)) was observed in the sublingual gland from our study, no malignant neoplasm was seen. This, however, contrast the study of Aliyu et al. (13) where all the neoplasms seen in the sublingual gland were malignant.

In contrast to the findings of Ajike et al. (33) on minor salivary glands having more of benign tumors, the present study have found out more of malignant lesions in the minor salivary glands.

Similar observation has been reported in the same region (13). The minor salivary glands consist of 800-1000 small mucus-secreting glands located throughout the lining of the oral cavity (2). Most of them are concentrated in the palate between the junction of the soft and hard palate. The present study has confirmed this location to have the highest number of cases. Similarly, studies have reported highest cases of minor SGN in this location (26, 34).

The present study has shown that mucoepidermoid carcinoma is the commonest malignant SGN and this is in tandem with reports from the literature (27, 35-36). However, other studies have reported adenocystic carcinoma as the commonest malignant SGN (19, 37-38). Adenocystic carcinoma was observed as the second most common malignant SGN in the current study. On the contrary Jude et al. (7) has reported adenocystic carcinoma as the commonest malignant SGN and mucoepidermoid carcinoma as the second most common malignant SGN. The literature is lucid about these two malignant lesions as the commonest lesions occurring in salivary glands globally (7). Polymorphous low grade adenocarcinoma was observed to be the 3rd most common malignant SGN in the current study. Although, this lesion has been reported to be rare (7), it is worthy to note that there should be high index of suspicion as this lesion usually presents painless, and most of the time in the palate which may be mistaking for pleomorphic adenoma.

In conclusion, the present study found a distribution ratio of 1.9:1.3:1:2.2 for parotid, submandibular, sublingual, and minor SGN. The peak incidences of benign and malignant tumors were in the 4th decade. Pleomorphic adenoma and mucoepidermoid carcinoma were the commonest benign and malignant SGN, respectively in our study population. SGN registry should be opened in all hospitals so as to have accurate data on the epidemiology and distribution of this diverse clinical entity.

Acknowledgement

The authors are grateful to the entire staff of the Departments of Dental and maxillofacial Surgery and Histopathology, Usmanu Danfodiyo University Teaching Hospital, Sokoto for the assistance given during data collation.

Conflict of interest

The authors declare that they have no competing interest.

References

- Miloro M, Ghali GE, Larsen PE, et al. Peterson's Principles of Oral and Maxillofacial Surgery. Hamilton, Ont.; London, B C Decker. 2004;672-7.
- Shah J P and Patel S G, Cancer of the Head and Neck. PMPH-USA. 2001;240.
- Gnepp R D. Diagnostic surgical pathology of the Head and Neck. Philadelphia: Saunders Elsevier. 2012; 413-38.
- Bradley J P. Classification of Salivary Gland Neoplasms. Adv Otorhinolaryngol. 2016;78:1-8.
- Eveson J W and Cawson R A. Salivary gland tumours: A review of 2410 cases with particular reference to histological type, site, age and sex distribution. J Pathol. 1985;146:51-8.
- Odell E W and Cawson R A. Cawson's essentials of oral pathology and oral medicine. Ninth edition: Elsevier. 2017.
- Jude U O and Olu-Eddo A N. Salivary gland tumors, a twenty-year retrospective study. Afr J Med Health Sci. 2014;13:24-9.
- Auclair P L, Ellis G L, Gnepp D R, et al., Salivary gland neoplasm: General consideration, in Surgical pathology of the salivary glands: Major problems in Pathology. Philadelphia: WB Saunders. 2000;135-64.
- Yaor M A. The pattern of presentation of salivary gland tumours in Africa: A review of published reports. Ear Nose Throat J. 2010;89:17.
- Hisham M, Andrew M, Max R, et al. Salivary gland swellings. BMJ. 2012;345:e6794.
- Barnes L, Eveson J, Reichart P, et al., World Health Organization Classification of Tumors: Pathology and Genetics of Head and Neck Tumors. Lyon: International Agency for Research on Cancer (IARC). 2005;209-81.
- Bahra J, Butt F, Dimba E, et al. Patterns of Salivary Tumours at a University Teaching Hospital in Kenya. OJST. 2012;2: 280-5.
- Aliyu D, Iseh K R, Sahabi S M, et al. Pattern of Salivary Gland Tumour in Sokoto, North-Western Nigeria. Int J Clin Med. 2016;7:347-52.
- Abiose B O, Oyejide O, Ogunniyi J. Salivary gland tumours in Ibadan, Nigeria: A study of 295 cases. Afr J Med Sci. 1990;19:195-9.
- Van Heerden W F P and Raubenheimer E J. Intraoral salivary gland neoplasms: A retrospective study of seventy cases in an African population. Oral Surgery, Oral Medicine, Oral Pathology and Oral Radiology. 1991;71:579-82.
- Otoh E C, Johnson N W, Olosoji H, et al. Salivary gland neoplasms in Maiduguri, north-eastern Nigeria. Oral Dis. 2005;11:386-91.
- Silas O A, Echejoh G O, Menasseh A N, et al. Descriptive Pattern of Salivary Gland Tumors in Jos University Teaching Hospital: A 10-Year Retrospective Study. Ann Afr Med. 2009;8:199-202.
- Chatterjee M T and Panda P K. A pathological study of benign and malignant tumours of salivary glands. Med J Armed Forces India. 2000;56:282-6.
- Vuhahula E A. Salivary gland tumors in Uganda: Clinical pathological study. Afr Health Sci 2004;4:15-23.
- Taiwo A O, Braitham R O, Ibikunle A A, et al. Oral and maxillofacial tumours in children and adolescents: Clinicopathologic audit of 75 cases in an academic medical centre, Sokoto, Northwest Nigeria. Afr J Paediatr Surg. 2017;14:37-42.
- Edington G M and Sheiham A. Salivary gland tumours and tumours of the oral cavity in western Nigeria. Br J Cancer. 1996;10:425-33.
- Kasangaki A and Kamulegeye A. Neoplasms of the salivary glands: A descriptive retrospective study of 142 cases-Mulago Hospital Uganda. J Contemp Dent Pract. 2004;5:16-27.
- Chidzonga M M, Lopez Perez V M, Portilla Alvarez A L. Salivary gland tumours in Zimbabwe: Report of 282 cases. Int J Oral Maxillofac Surg. 1995;24:293-7.
- Onyango J F, Awange D O, Muthamia J M, et al. Salivary gland tumours in Kenya. East Afr Med J. 1992;69:525-30.
- Jones A V, Craig G T, Speight P M, et al. The range and demographics of salivary gland tumours diagnosed in a UK population. Oral Oncol. 2008;44:407-17.
- Massanja M I, Kalvanyama B M, Simon E N. Salivary gland tumours in Tanzania. East Afr Med J. 2003;80:429-34.
- Elumelu T N, Folasire A M, Ntekim A I, et al. Salivary Gland

Tumors in Nigerian Patients – a 10 year review. *J Cancer Biol Res.* 2014;2:1054-60.

28. Shaikh A M, Kehar S I, Tariq N. Spectrum of salivary gland lesions and frequency of adenoid cystic carcinoma in salivary glands and extra salivary sites. *Pak J Otolaryngol.* 2010;26:37-39.

29. Ito F A, Ito K, Vargas P A, et al. Salivary gland tumours in a Brazilian population. A retrospective study of 496 cases. *Int J Oral Maxillofac Surg.* 2005;34:533-6.

30. Oti A A, Donkor P, Obiri-Yeboah S, et al. Salivary Gland Tumours at Komfo Anokye Teaching Hospital, Ghana. *Surgical Science.* 2013;4:135-9.

31. Nzegwu M A, Njeze N R, Ugochukwu A I, et al. A Review of Salivary Gland Neoplasms in Eastern Nigeria For A Five-Year Period from January 1, 2000 to December 31st 2004. *Adv Biores.* 2011;2:28-32.

32. Taiwo O A, Olusola A S, James E T. Clinico-Pathologic Spectrum of Salivary Gland Tumours and Its Management in a Suburban Tertiary Centre. *Adv Biomed Res.* 2014;5:124-9.

33. Ajike S O, Adebayo A T, Adekeye E O. Minor salivary gland tumours in Kaduna, Nigeria. *Nig J Surg Research.* 2003;5:100-5.

34. Ochicha O, Salami S, Mohammed A, et al. A histopathologic study of salivary gland tumours in Kano, northern Nigeria. *Indian J Pathol Microbiol.* 2009;52:473-6.

35. Rajesh S L, Arum K K, Gayatri D P, et al. Pattern of Salivary gland tumours in Manipuur, India: A 10 year study. *South Asian J Cancer.* 2013;2:250-3.

36. Pinkston J A and Cole P. Incidence rates of salivary gland tumours: Results from a population-based study. *Otolaryngol Head Neck Surg.* 1999;120:834-40.

37. Moatemri R, Belajouza H, Farroukh U, et al. Epidemiological profile of salivary-glands tumors in a Tunisian teaching hospital. *Rev Stomatol Chir Maxillofac.* 2008;109:148-52 [Article in French].

38. Tian Z, Li L, Wang L, et al. Salivary gland neoplasms in oral and maxillofacial regions: A 23-year retrospective study of 6982 cases in an eastern Chinese population. *Int J Oral Maxillofac Surg.* 2010;39:235-42.