

Hepatotoxicity and ALT/AST Enzymes Activities Change in Therapeutic and Toxic Doses Consumption of Acetaminophen in Rats

Pouria jarsiah¹, Anahita Nosrati², Ahad Alizadeh³, Mohammad Bagher Hashemi-Soteh^{4*}

1. Department of Toxicology and Pharmacology, Faculty of Pharmacy, Mazandaran University of Medical Sciences, Sari, Iran.

2. Laboratory of Pathobiology, Imam Khomeini Hospital, Sari, Iran.

3. Department of Epidemiology and Reproductive Health, Reproductive Epidemiology Research Center, Royan Institute for Reproductive Biomedicine, ACECR, Tehran, Iran.

4. Immunogenetic Research center, Molecular and Cell biology Research Center, Faculty of Medicine, Mazandaran University of Medical Sciences, Sari, Iran.

Submitted 7 May 2017; Accepted 23 Jun 2017; Published 1 Jul 2017

Acetaminophen (APAP) poisoning is the most common drug intoxication, which often leads to acute liver failure (ALF). In this study, the effects of different doses of APAP on aminotransferases (AST and ALT) and liver pathological lesions were assessed in young rats. 32 male albino Wistar rats were randomly selected and divided into eight groups. In case groups, three groups after one hour, and 3 groups after three hours were sampled and sacrificed after intraperitoneal injection of 70, 150 and 300 mg/Kg.bw APAP. The variances of necropsy and macroscopic features were recorded after fixation in 10% formalin and staining with hematoxylin and eosin. There was no pathological change in the one or three hours at 75 mg/kg. The 150 mg/kg dose caused mild hyperemia and edema of the portal areas and mild infiltration of inflammatory cells at both one hour and three hours time points. Centrilobular necrosis was mild at 300 mg/kg after one and three hours, and hepatocellular necrosis was sporadically and slightly elevated for this dose after one hour. Based on multivariate variance analysis test (MANOVA), both dose and time exerted significant effects on ALT and AST activities in the case groups at the first and third hours ($P < 0.05$). Due to the ability to induce a protective system against acetaminophen toxicity, ALT plasma level evaluation in the early hours will be more helpful than measuring AST level.

Keywords: Acetaminophen, drug toxicity, ALT, AST, hepatic necrosis, rat

Acetaminophen (APAP, Paracetamol) is one of the most popular drugs in the world, which was first introduced and used in 1893 by Von Mering to treat pain and fever. The effect of the drug starts about 12 minutes after its oral administration. Due to high drug administration, poisoning with this medicine is one of the most common cases of

poisoning in the world starting with symptoms such as malaise, vomiting, diarrhea, and sometimes shock. Also, in excessive consumption it can lead to liver necrosis and jaundice in animals and humans. In some cases, it has been observed to cause simultaneous myocardial and renal damages (1-4).

Although acetaminophen is a safe drug, and

*Correspondence: Immunogenetic Research center, Molecular and Cell biology Research Center, Faculty of Medicine, Mazandaran University of Medical Sciences, Sari, Iran. E-mail: hashemisoteh@gmail.com

the distance between a therapeutic dose (0.5 g) and its toxic dose (15-25 g) is relatively high and is associated with little risk for its consumers, severe liver toxicity from acetaminophen poisoning often lead to acute liver failure (ALF). Also, studies have found that liver tissue necrosis would occur following the consumption of excessive amounts of acetaminophen as an analgesic and antipyretic drug (2, 5-6). In individuals receiving toxic doses of acetaminophen, extensive necrosis of liver cells is observed after 24 hours and reaches its maximum in the following 3-4 days (7). It was found through experimental studies in animals that cytochrome P450 inhibitors can inhibit hepatotoxicity caused by acetaminophen, and cytochrome P450 inducers may escalate it (1, 8).

The aim of the present study was to investigate the relationship between anti-oxidative system induced by acetaminophen and pathological lesions in the liver of young rats. The effects of toxic and therapeutic doses of acetaminophen on enzymatic and non-enzymatic antioxidant factors, the total antioxidant capacity of serum, hepatic transaminases (aspartate aminotransferase (AST) and alanine aminotransferase (ALT)), and pathological lesions in the liver of young rats were studied and the levels of serum AST and ALT and histopathological lesions in the liver during the first and third hours of acetaminophen administration were compared.

Materials and methods

Animals

In this study, 32 male albino Wistar rats (aged approximately 1.5 to 3 months and weighing 110 ± 25 g) were randomly selected and divided into 8 four-member groups with similar conditions. The first three groups were sampled in the first hour after drug injection, while for the second three batches, sampling was done 3 hours after acetaminophen injection. In the case group, the toxic and therapeutic doses (70, 150 and 300 mg/Kg.b.w) of acetaminophen were injected once intraperitoneally

(IP), respectively. For two control groups, only phosphate buffered saline (PBS) (100 mM, pH= 7.4) with polyethylene glycol 200 (200 PEG) as a solvent was used.

Histopathological study

Since the relationship between the degree of drug toxicity and liver damages was being assessed, the pathological method was used as the gold standard to determine liver damages. Following blood sampling, all the rats were sacrificed 1 and 3 hours after drug injection. After recording the macroscopic tissue changes, the liver of tested rats were fixed in 10% formalin. After routine pathological processing, 5 micrometers thick sections were prepared and stained with hematoxylin and eosin.

Hepatocytes necrosis (spotty necrosis), the inflammation rate in the portal area as well as inflammatory cell infiltration, centerilobular necrosis, and decreased cellular glycogen were used for pathological evaluation of the liver status. The damage severity was assessed as graded from zero to three (0= no damage, 1= mild damage, 2= moderate damage, 3= severe damage). All prepared slides were examined thoroughly by light microscopy.

Biochemical tests

3 ml of the blood samples was taken directly from the heart using complete ether anesthesia. The sera were collected by centrifugation, and maintained at -20°C . The levels of liver enzymes (AST and ALT) in the serum samples were measured (IU/L) using the commercial enzymatic kits of Biorex fars Company by automated analyzer device (HITACHI 911).

Statistical analysis

The quantitative information was obtained and changes in liver enzymes in the case and control groups were statistically analyzed by R and SPSS softwares. Due to the lack of homogeneity of variances, the Box-Cox transformation was used to normalize the data (9).

Results

Histopathological findings

Histopathology of the liver in control group rats at a dose of 75 mg/Kg in one hour and three hours groups showed no specific pathological changes. Effects of acetaminophen began to appear from 150 mg/Kg dose (both one hour and three hours groups) in form of mild hyperemia and edema of the portal area and mild infiltration of inflammatory cells.

At 300 mg/Kg dose, in both one-hour and three-hours groups, the centerilobular necrosis was mild, while scattered necrotic hepatocytes (spotty necrosis) was slightly elevated in one hour group in comparison with three hours group. Results are summarized in table 1 and figure 1.

Biochemical findings

Table 2 represents the rates of ALT and AST changes at the first and third hours in the control and acetaminophen receiving groups in the presence of varying doses of drug.

Based on multivariate analysis of variance

(MANOVA), both main effects (dose and time) and their interactions were significant (dose: Wilks' $\lambda = 0.228$, $P < 0.001$; time: Wilks' $\lambda = 0.456$, $P < 0.001$; and interaction of them: Wilks' $\lambda = 0.493$, $P = 0.010$). In other words, ALT activities (IU/L) at doses ≥ 75 IU/L at the first and third hours were significantly different from each other (dose 75 IU/L: $P < 0.002$, dose 150 IU/L: $P = 0.025$, and dose 300 IU/L: $P < 0.001$) (table 2). According to Wilks' λ index, 45.6% of changes in both ALT and AST levels were not related to the time, and also 22.8% of the enzyme changes were not related to dosage.

Regarding MANOVA method, there was a significant relationship between the activity of ALT and AST and time and dose factors ($P < 0.001$ and $R = 0.784$) (figure 2, C). It is shown that all factors were significant for ALT, while for AST; only the dose effect is significant. According to the R Squared index, 72.1% of ALT enzyme changes were related to both dose and time. Regarding AST enzyme, 55.8% of the variations were related to both dose and time (figure 2, A and B).

Table 1. Histopathology features of control and treated groups

Pathology state	Groups	Control 1h	Control 3h	75 mg/kg 1h	75 mg/kg 3h	150 mg/kg 1h	150 mg/kg 3h	300 mg/kg 1h	300 mg/kg 3h
Portal area inflammation and hematoma	Grade 1					+	+	+	+
	Grade 2								
	Grade 3								
Liver cell necrosis (spotty necrosis)	Grade 1								+
	Grade 2							+	
	Grade 3					+	+		
Infiltration of inflammatory cells	Grade 1								
	Grade 2							+	
	Grade 3								
Centrilobular necrosis and glycogen decrease in cell	Grade 1								
	Grade 2							+	+
	Grade 3								

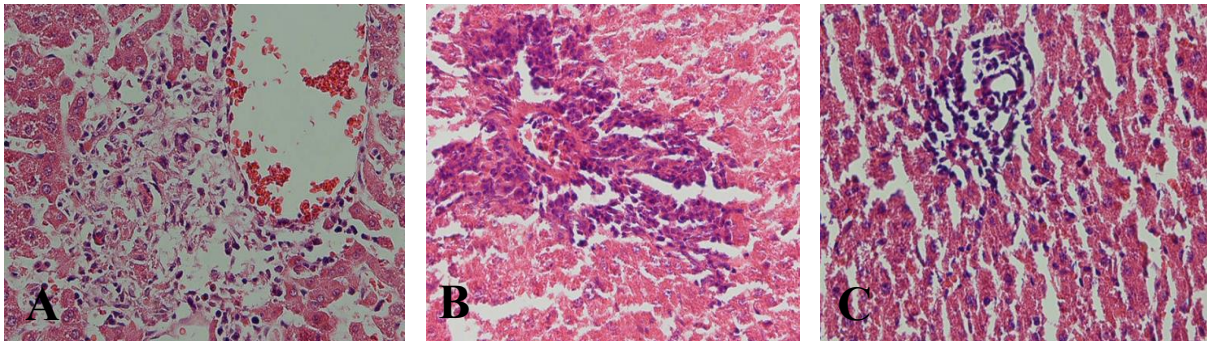


Figure 1. Photomicrograph of histopathologic examination of livers. Hematoxylin and eosin stained slides of livers (400x magnification) of rats treated with 300 mg/Kg acetaminophen. A: centrilobular necrosis; B: portal tract inflammation; C: spotty necrosis.

Table 2. ALT and AST levels (IU/L) in plasma of rats treated with different doses of acetaminophen

Time (hours)	AST (Mean±SD)	ALT (Mean±SD)	Dosage (mg/kg)
1	183.5±6.5	70.5±7	Control
	307.3±138	70.5 ± 8	75
	227.5±40	90.0±8	150
	251.2±75	78.0±7	300
3	187.0±8	68.2±10	Control
	365.5±156	143.2±88	75
	293.2±124	151.5±65	150
	347.5±135	162.5±35	300

Controls received no drug. ALT: alanine aminotransferase; AST: aspartate aminotransferase; SD: standard deviation.

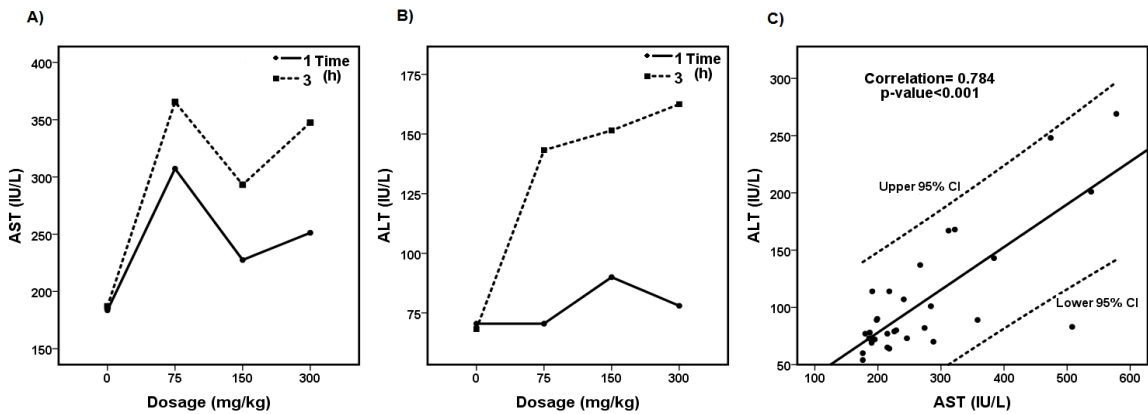


Figure 2. The rates of ALT and AST activities (IU/L) in the receiving acetaminophen groups at different times (A and B). The correlation between activity of ALT and AST enzymes and time and dose factors are shown in graph C.

Discussion

Correlations between overuse of acetaminophen and hepatotoxicity, as well as the extent of glutathione (GSH) depletion and covalent bonding have been observed in animals and humans (1-2, 4, 8, 10-11). In the present study, hyperemia

and edema of the portal area, hepatocellular necrosis (spotty necrosis), and inflammatory cells infiltration were observed. Also centrilobular necrosis and loss of cellular glycogen were observed in the rats receiving high and toxic doses of acetaminophen.

Different studies showed previously that

overuse of acetaminophen in mice and rats can cause severe and extensive necrosis cells in the centrilobular area in the liver, and increased serum ALT/AST levels in rats which is in line with the results of the present study (4, 8, 10-12). Acetaminophen toxicity causes hepatocytes necrosis within the centers of liver lobules, sometimes extending throughout them. Some differences are seen in sensitivity to paracetamol within different species, so that in most rat strains acetaminophen is primarily hepatotoxic, but in others such as Fischer 344 strain, acetaminophen shows nephrotoxic effects (1-2). Dadkhah and colleagues conducted a study on adult and newborn rats in 2007 and found liver lesions in adult rats, which was in accordance with our findings (13). Ben-Shachar et al. also used a mathematical model to evaluate the effects of different doses of acetaminophen on the GSH and liver metabolism of APAP. They showed that the mathematical model could be used to study the metabolism of acetaminophen, if the expression levels of hepatic enzymes are known (14). In this model, the plasma ALT enzyme levels showed significant differences at different doses and times which was also consistent with the results achieved in the present study (14).

In a recent study, Heard and colleagues investigated 252 healthy outpatient volunteers treated with 4 g acetaminophen daily, or placebo for 16 days, 23% showed ALT elevations on acetaminophen while 2% of volunteers on placebo showed peak values (highest 191 U/L) at days 7-10. The ALT elevations in volunteers on acetaminophen were above normal in 9% and above twice normal in 3% versus none in volunteers on placebo (15). In another study on humans, 94 adults with asthma were treated with acetaminophen (2 g daily) or placebo for 12 weeks. ALT elevations above 3 times ULN arose in 1 subject in both groups, and mean ALT levels were minimally increased from 23.6 to 25.4 U/L, but did not change for those receiving placebo (16). Other studies also showed that

ALT/AST levels increased with low doses of APAP due to cardiopulmonary and renal insufficiencies (17-18).

The cell death mechanisms due to APAP consumption in mice and humans are initiated by the formation of the reactive metabolite N-acetyl-p-benzoquinone imine (NAPQI), which is generated mainly by the cytochrome P450 enzymes Cyp2E1 and Cyp1A2 (19). NAPQI is usually detoxified by conjugation with GSH, but the availability of GSH is limited in case of overdose (19). Investigations also showed that in mouse models and in humans, APAP-induced liver injury involves mitochondrial damage, oxidative stress, c-jun N-terminal kinase (JNK) activation, and nuclear DNA fragmentation. However, the mechanisms of injury and cell death are different in rats and happen almost always due to apoptosis (15, 19).

In conclusion, our data showed that APAP overdose can cause liver injury and plasma ALT/AST enzyme increase. Furthermore the evaluation of plasma ALT activity in the early hours would be more helpful than AST levels measurement.

Acknowledgement

This article is the result of the Master's thesis in Toxicology by Pouria Jarsiah. We would like to acknowledge the staff of animal laboratory research center of Mazandaran University of Medical Sciences, Dr. Makhloogh and all those who helped us in this project.

Conflict of interest

The authors declared no conflict of interest.

References

1. McGee J O D, Isaacson P G, Wright N A. Oxford Textbook of Pathology: Pathology of Systems. Vol. 2a-b: Oxford University Press; 1992.
2. Kumar V, Abbas A, Fausto N. Melatonin in. Robbins and Cotran Pathologic Basis of Diseases. Elsevier Saunders; 2005.
3. Prescott L F. Paracetamol: past, present, and future. Am J Ther. 2000;7:143-8.
4. Ray S D, Mumaw V R, Raje R R, et al. Protection of acetamin-

- ophen-induced hepatocellular apoptosis and necrosis by cholesteryl hemisuccinate pretreatment. *J Pharmacol Exp Ther*. 1996;279:1470-83.
5. Lee W M, editor. Acute liver failure. Seminars in respiratory and critical care medicine. Thieme Medical Publishers; 2012.
 6. Lee W M. Acetaminophen and the US Acute Liver Failure Study Group: lowering the risks of hepatic failure. *Hepatology*. 2004;40:6-9.
 7. Khorsandi L, Javadnia F, Orazizadeh M, et al. Effect of green tea (*Camellia sinensis* L.) extract on acetaminophen induced acute hepatotoxicity in mice. *Iranian Journal of Medicinal and Aromatic Plants*. 2010;26:22-9.
 8. Shon Y-H, Nam K-S. Protective effect of Moutan Cortex extract on acetaminophen-induced hepatotoxicity in mice. *J Ethnopharmacol*. 2004;90:415-9.
 9. Weisberg S. Applied linear regression: John Wiley & Sons; 2005.
 10. Song Z, McClain C J, Chen T. S-Adenosylmethionine protects against acetaminophen-induced hepatotoxicity in mice. *Pharmacology*. 2004;71:199-208.
 11. Sakaue T, Matsumoto S, Tsuboi S, et al. Protective effect of S-(1, 2-dicarboxyethyl) glutathione, an intrinsic tripeptide in liver, heart and lens, and its esters on acetaminophen-induced hepatotoxicity in rats. *Biol Pharm Bull*. 1996;19:1216-9.
 12. Du K, Farhood A, Jaeschke H. Mitochondria-targeted antioxidant Mito-Tempo protects against acetaminophen hepatotoxicity. *Arch Toxicol*. 2017;91:761-73.
 13. Dadkhah A, Allameh A, Fatemi F, et al. Considering the pathologic lesions of liver and changes of plasma alanine transaminase and aspartate transaminase in acetaminophen-induced toxicity in rat. *Pharm Sci*. 2007;2:47-54.
 14. Ben-Shachar R, Chen Y, Luo S, et al. The biochemistry of acetaminophen hepatotoxicity and rescue: a mathematical model. *Theor Biol Med Model*. 2012;9:55.
 15. Heard K, Green J L, Anderson V, et al. A randomized, placebo-controlled trial to determine the course of aminotransferase elevation during prolonged acetaminophen administration. *BMC Pharmacol Toxicol*. 2014;15:39.
 16. Ioannides S J, Siebers R, Perrin K, et al. The effect of 1g of acetaminophen twice daily for 12weeks on alanine transaminase levels—A randomized placebo-controlled trial. *Clin Biochem*. 2015;48:713-5.
 17. Lee P J, Shen M, Wang S, et al. Possible hepatotoxicity associated with intravenous acetaminophen in a 36-year-old female patient. *Pharmacol Ther*. 2015;40:123-32.
 18. Bonkovsky H L, Kane R E, Jones D P, et al. Acute hepatic and renal toxicity from low doses of acetaminophen in the absence of alcohol abuse or malnutrition: evidence for increased susceptibility to drug toxicity due to cardiopulmonary and renal insufficiency. *Hepatology*. 1994;19:1141-8.
 19. Jaeschke H, Xie Y, McGill M R. Acetaminophen-induced liver injury: from animal models to humans. *J Clin Transl Hepatol*. 2014;2:153-61.