

## The First Iranian Case of Mucopolysaccharidosis IIIC: Use of Homozygosity Mapping in a Consanguineous Pedigree

Atieh Eslahi<sup>1</sup>, Farah Ashrafzadeh<sup>2</sup>, Kazem Hasanpour<sup>3</sup>, Majid Mojarrad<sup>1,4\*</sup>,  
Nedasadat Hosseini<sup>1</sup>

1. Department of Medical Genetics, School of Medicine, Mashhad University of Medical Sciences, Mashhad, Iran.

2. Department of Pediatric Neurology, Ghaem Medical Center, Mashhad University of Medical Sciences, Mashhad, Iran.

3. Department of Clinical Sciences, Sabzevar University of Medical Sciences, Sabzevar, Iran.

4. Medical Genetics Research Center, School of Medicine, Mashhad University of Medical Sciences, Mashhad, Iran.

Submitted 10 Apr 2018; Accepted 24 May 2018; Published 19 Jul 2018

Mucopolysaccharidosis type IIIC (MPSIIIC) is a rare subtype of mucopolysaccharidosis disorder family caused by mutations in heparan-alpha-glucosaminide N-acetyltransferase (*HGSNAT*) gene. MPSIIIC is subdivided into four subtypes which have overlapping features, and are indistinguishable at clinical level. In populations with high consanguineous marriage rate, homozygosity mapping can be a good choice for finding a disease locus. Herein we report a female patient with a novel mutation in *HGSNAT* gene in Iranian population. Clinical diagnosis was accomplished based on clinical manifestations, and urine biochemical analysis. Homozygosity mapping was performed using SNP- array technology to narrow down the candidate locus. All coding exons of *HGSNAT* were scanned by direct DNA sequencing. We found a novel ins/del mutation as c.1357TA>C. This mutation is a frameshift which eventually leads to premature protein truncation. To the best of our knowledge this is the first case report of Sanfilippo type C in Iranian population. This result also supports the applicability of homozygosity mapping to the diagnosis of Sanfilippo subtype.

**Keywords:** Mucopolysaccharidosis type IIIC, *HGSNAT*, homozygosity mapping, SNP-array, mutation detection

Mucopolysaccharidosis type III (MPS III), also known as Sanfilippo syndrome is a rare autosomal recessive lysosomal storage disorder. MPS III is caused by deficiency or absence of 1 of the 4 lysosomal enzymes that break down glycosaminoglycan (GAG) heparan sulfate. Accordingly, MPS III is subdivided into 4 subtypes, labeled A-D, based on deficiency or missing of the specific lysosomal enzyme (1-4).

The clinical features and symptoms of the 4

subtypes of MPS III overlap, and are not easily distinguishable. Thus, there is a possibility of misdiagnosis in some patients with different subtypes of MPS III.

Severe progressive degeneration of the central nervous system (5, 6), seizures, sleep disorder, autistic features, speech deficiency, and mental retardation may occur due to accumulation of heparan sulfate in the brain. Hepatomegaly, umbilical hernia, joint stiffness, and ovoid vertebral

\*Correspondence: Internal Medicine Department, State Medical University for Zaporozhye, Zaporozhye, Ukraine.  
E-mail: mojaradm@mu.ms.ac.ir

shaped vertebral bodies are common symptoms in MPSIII subtypes.

Subtypes of MPSIII have different prevalence. IIIA and IIIB subtypes are the most common types, while subtypes IIIC and IIID are less prevalent (7).

MPS IIIA, also called Sanfilippo syndrome type A is caused by deficiency of the heparan N sulfatase enzyme. MPS IIIB or Sanfilippo syndrome type B is due to a deficiency in  $\alpha$ -N-acetylglucosaminidase. Both genes associated with MPS IIIA and MPS IIIB are located on the long arm of chromosome 17, 17q25 and 17q21, respectively.

Deficiency of N-acetylglucosamin 6-sulfatase causes MPS IIID. The gene that causes MPS IIID is located on the long arm of chromosome 12q14 (1).

The most rare form of MPSIII, MPS IIIC, is caused by deficiency in heparan acetyl-coA: alpha-glucosaminide N-acetyltransferase enzyme (HGSNAT), and breaks down a glycosaminoglycan (GAG) called heparan sulfate (7). The corresponding gene is located on chromosome 8p11.1.

The primary laboratory diagnosis of the MPS III relies on increased concentrations of GAG heparan sulfate in the urine. Specific enzyme assay on fibroblast or leukocyte sample is a reliable method for precise differential diagnosis of MPS III subtypes. However, this method is labor intensive and less available (1, 2).

Mutation detection in these genes is the most reliable diagnostic tool for detection of MPSIII subtypes. However, the large size and large number of coding exons make molecular diagnosis of MPSIII subtypes time and cost consuming.

Homozygosity mapping can be used for the tracking of mutated locus in consanguineous families.

Moreover, molecular detection of disease causing mutations is required for definite diagnosis, and also prenatal diagnosis.

In the present study, we report an Iranian case of Sanfilippo type IIIC diagnosed by genetic mapping and whole gene sequencing.

## Case presentation

### Clinical findings

The patient was a 6 years old girl, first child of family, suffering from aggressiveness, hyperactivity, and poor attention. The parents were healthy consanguineous (first cousins).

She was born at term with normal vaginal delivery, and good Apgar. Her height was 118 cm and head circumference was 52 cm at the time of evaluation.

She had a surgery for umbilical hernia. On physical examination, mild coarse facial features, nasal bridge repression, and filled eyebrows were prominent.

She had speech delay, hyperactivity, poor attention, and autistic behavior which became worth during the last two years.

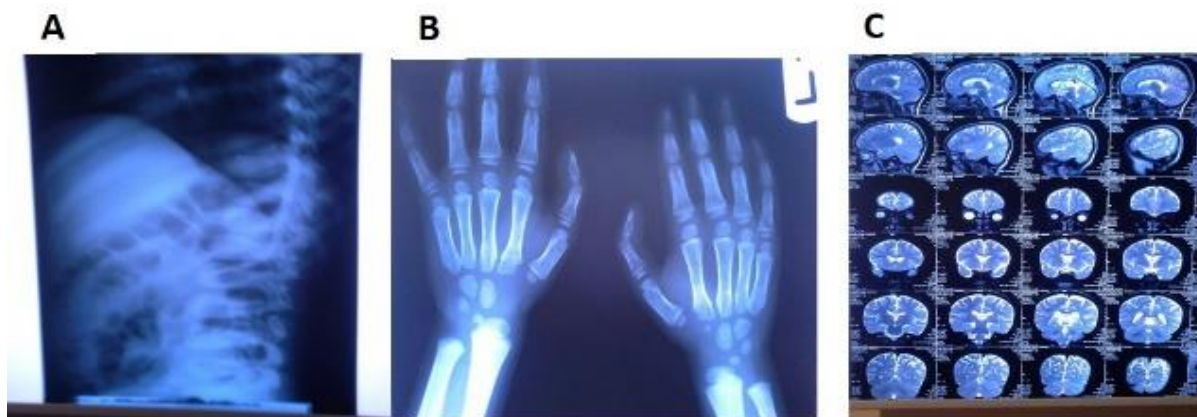In radiologic evaluation, lumbar spine showed ovoid shaped vertebral bodies (fig-1a). Both hands suffered from widening of metacarpals (fig-1b). Furthermore, brain MRI revealed mild ventricularomegaly, and cortical atrophy (fig-1c). Serum amino acid profile, metabolic screening results (performed by MS/MS), and urine organic acid profile were in normal range. Thin layer chromatography of urine showed elevated heparan sulfate levels which suggested MPSIII.

### Homozygosity mapping using SNP array

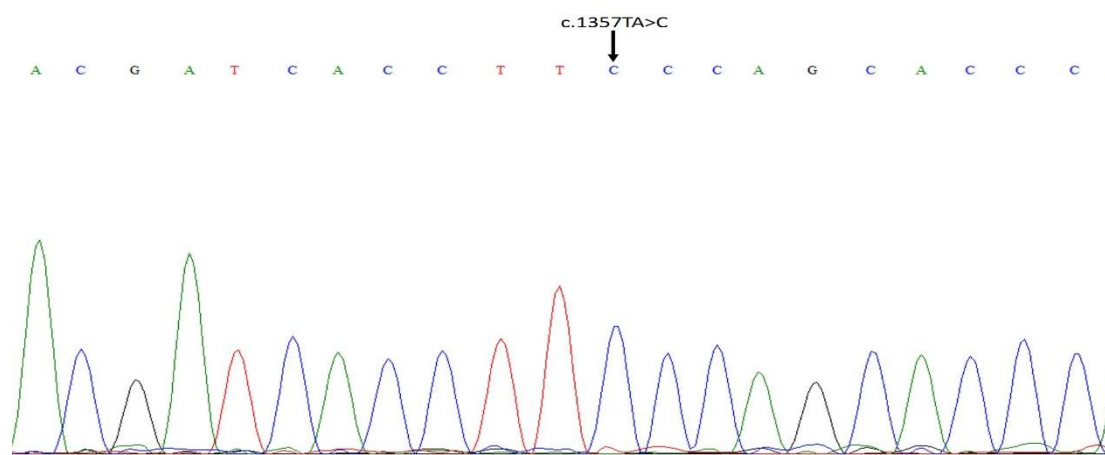
In order to localize the chromosomal location of the pathogenic variant, we genotyped samples from affected child and his unaffected sibling genome-wide by using Illumina Human CytoSNP-12 V2.1 bead chip array incorporating ~330,000 genetic markers. Homozygosity mapping revealed the presence of a notable homozygous region in chr8p12-p21.11. This homozygosity box has 44.5 Mb length and harbors the most uncommon form of MPSIII (Sanfilippo syndrome) gene, *HGSNAT* (fig-2). Unaffected sibling did not show a run of homozygosity in this region.

### DNA sequencing

To detect the responsible mutation in this



**Figure 1.** Imaging of MPSIIIC patient's body. A: beaking of vertebrae, and widening of the ribs; B: widened tubular bones, and expanded metacarpal bones; C: MRI results of patients brain where no major anomaly was observed.



**Figure 2.** Sequencing result for *HGSNAT* gene. There is a homozygous mutation replacing TA with C which leads to frameshift and premature stop codon formation.

patient, all of *HGSNAT* exons were amplified by PCR. To detect the responsible mutation in this patient, all of *HGSNAT* exons were amplified by PCR. Sequences of used primers are available on request. All of PCR products were sequenced bidirectionally. Finally, c.1357TA>C was detected in homozygous state (fig-2). Patient's parents were heterozygous for this mutation. This mutation was a frameshift mutation which causes reading frame change, and eventually leads to premature stop codon. This mRNA may be subject to "non-sense mediated mRNA decay", and total loss of *HGSNAT* function.

## Discussion

Sanfilippo syndrome type C is caused by acetyl coA- $\alpha$ -glucosaminide N-acetyl transferase

deficiency. This enzyme is involved in glycosaminoglycan heparan sulphate degradation which its accumulation leads to cell cytotoxicity as the basis of disease pathophysiology.

The frequency of MPSIIIC varies among MPS patients population around the world. MPS IIIC accounts for approximately 18% of Korean patients with MPS, and 12.4% of the total MPS III in the Spanish population (8-12).

Most MPS III type C patients start to manifest disease symptoms in infancy or early childhood. Rarely some patients with MPS IIIC show adulthood onset of clinical symptoms (13). The genetic defect underlying MPS IIIC was identified only 5 years ago. Thus, a few documents are available about MPS IIIC syndrome (14-16).

To date, there is no any therapeutic approach for MPS IIIC. Medical interventions are limited to symptomatic medication such as flavonoid genistein, which decreases the pathological accumulation of GAGs. Furthermore, rhodamine B, an effective inhibitor of GAGs production *in vitro* and *in vivo*, may also be used to treat MPSII subtypes (6).

Treatments based on deficient enzyme replacement do not show promising results for MPSII disorders. This failure is due to inability of the enzyme to pass through the blood-brain barrier (2).

Recently, Clinical trials using direct injection of purified enzyme or viral vectors harboring enzyme coding sequence into the intracranial space showed promising positive results. The use of recombinant viruses that infect the central nervous system can be an attractive therapeutic option in the gene therapy studies for MPS IIIC in the near future (17-19).

Approximately 54 mutations have been reported in *HGSNAT* gene so far. These include 18 missense mutations, 13 splicing site mutations, 11 insertion and deletion mutations, 8 nonsense mutations and 4 polymorphisms (3, 20).

All MPSII subtypes are autosomal recessive disorders, and therefore both enzyme coding alleles must be mutated to create the disease. Considering the low frequency of these disorders, most of MPSII patients are expected to be result of consanguineous marriage. So most of these patients have identical by descent (IBD) disease alleles.

With that in mind, homozygosity mapping methods can be a promising approach to narrow down MPSII subtype diagnosis. In next step, direct sequencing can be used for confirming diagnosis.

Here, we report a Sanfilippo type C case which was diagnosed using this strategy. A novel mutation designated as c.1357TA>C in coding sequence of *HGSNAT* gene was detected in this patient. This mutation results in frame shift, and produces a

nonsense mutation residue downstream of mutation site which eventually leads to premature protein truncation and probably nonsense mediated mRNA decay. Therefore, the C.1357TA>C mutation is thought to be a disease causing mutation.

Patient's parents were first cousin relatives, so it seems that the mutation identified in this family originated from a common ancestor. To the best of our knowledge, this is the first report of MPS IIIC in Iranian population.

### Conflict of interest

The authors declare that they have no competing interest.

### References

1. Huh H J, Seo J Y, Cho S Y, et al. The first Korean case of mucopolysaccharidosis IIIC (Sanfilippo syndrome type C) confirmed by biochemical and molecular investigation. *Ann Lab Med*. 2013;33:75-9.
2. Heron B, Mikaeloff Y, Froissart R, et al. Incidence and natural history of mucopolysaccharidosis type III in France and comparison with United Kingdom and Greece. *Am J Med Genet A*. 2011;155A:58-68.
3. Feldhammer M, Durand S, Mrazova L, et al. Sanfilippo syndrome type C: mutation spectrum in the heparan sulfate acetyl-CoA: alpha-glucosaminide N-acetyltransferase (*HGSNAT*) gene. *Hum Mutat*. 2009;30:918-25.
4. Garbuzova-Davis S, Mirtyl S, Sallot S A, et al. Blood-brain barrier impairment in MPS III patients. *BMC Neurol*. 2013;13:174.
5. Neufeld E, Muenzer J. The mucopolysaccharidoses. McGraw-Hill, New York. 2001;3421-3452.
6. Valstar M J, Ruijter G J, Van Diggelen O P, et al. Sanfilippo syndrome: a mini-review. *J Inher Metab Dis*. 2008;31:240-52.
7. Canals I, Elalaoui S C, Pineda M, et al. Molecular analysis of Sanfilippo syndrome type C in Spain: seven novel *HGSNAT* mutations and characterization of the mutant alleles. *Clin Genet*. 2011;80:367-74.
8. Meikle P J, Hopwood J J, Clague A E, et al. Prevalence of lysosomal storage disorders. *JAMA*. 1999;281:249-54.
9. Pinto R, Caseiro C, Lemos M, et al. Prevalence of lysosomal storage diseases in Portugal. *Eur J Hum Genet*. 2004;12:87-92.
10. Poorthuis B J, Wevers R A, Kleijer W J, et al. The frequency

of lysosomal storage diseases in The Netherlands. *Hum Genet.* 1999;105:151-6.

11. Malm G, Lund a M, Mansson J E, et al. Mucopolysaccharidoses in the Scandinavian countries: incidence and prevalence. *Acta Paediatr.* 2008;97:1577-81.

12. Lin H Y, Lin S P, Chuang C K, et al. Incidence of the mucopolysaccharidoses in Taiwan, 1984-2004. *Am J Med Genet A.* 2009;149A:960-4.

13. Berger-Plantinga E G, Vanneste J A, Groener J E, et al. Adult-onset dementia and retinitis pigmentosa due to mucopolysaccharidosis IIIC in two sisters. *J Neurol.* 2004;251:479-81.

14. Fan X, Zhang H, Zhang S, et al. Identification of the gene encoding the enzyme deficient in mucopolysaccharidosis IIIC (Sanfilippo disease type C). *Am J Hum Genet.* 2006;79:738-44.

15. Hrebicek M, Mrazova L, Seyrantepe V, et al. Mutations in TMEM76\* cause mucopolysaccharidosis IIIC (Sanfilippo C

syndrome). *Am J Hum Genet.* 2006;79:807-19.

16. Ruijter G J, Valstar M J, Van De Kamp J M, et al. Clinical and genetic spectrum of Sanfilippo type C (MPS IIIC) disease in The Netherlands. *Mol Genet Metab.* 2008;93:104-11.

17. Mader K M, Beard H, King B M, et al. Effect of high dose, repeated intra-cerebrospinal fluid injection of sulphamidase on neuropathology in mucopolysaccharidosis type IIIA mice. *Genes Brain Behav.* 2008;7:740-53.

18. Hemsley K M, Norman E J, Crawley a C, et al. Effect of cisternal sulfamidase delivery in MPS IIIA Huntaway dogs—a proof of principle study. *Mol Genet Metab.* 2009;98:383-92.

19. White K K, Karol L A, White D R, et al. Musculoskeletal manifestations of Sanfilippo Syndrome (mucopolysaccharidosis type III). *J Pediatr Orthop.* 2011;31:594-8.

20. Feldhammer M, Durand S, Pshezhetsky a V. Protein misfolding as an underlying molecular defect in mucopolysaccharidosis III type C. *PLoS One.* 2009;4:e7434.