

Effects of Orally Administered Lead acetate II on Rat Femur Histology, Mineralization Properties and Expression of Osteocalcin Gene

Hossein Rafiei¹, Zahra Ahmadi², Milad Ashrafizadeh^{3*}

1. Department of Biology, Faculty of Sciences, Shiraz Branch, Islamic Azad University, Shiraz, Iran.

2. Department of Basic Sciences, Veterinary Medicine faculty, Shushtar Branch, Islamic Azad University, Khuzestan, Iran.

3. Department of Basic Sciences, Veterinary Medicine faculty, Tabriz University, Tabriz, Iran.

Submitted 6 Aug 2018; Accepted 30 Sep 2018; Published 3 Oct 2018

Lead is one of the harmful heavy metals that may be produced from human activities, and have deleterious effects on many tissues such as bone. In this research, the effects of oral administration of lead acetate II on histology of rat femur, and expression level of osteocalcin gene were investigated. Twenty male Wistar rats were randomly divided into 2 groups. The rats in tested group were fed with 100 ppm of lead acetate II during 2 months. The femur samples were removed, fixed and then stained by alizarin red S for mineralization ratio assessment, and Hematoxylin-Eosin for histological studies. Also, real-time PCR was performed to determine the expression level of osteocalcin gene. The dose of 100 ppm of lead acetate II reduced mineralization and bone density, and decreased the relative density of osteoblasts. Also, the diameter of the bone marrow increased while the expression of osteocalcin gene decreased in tested group in comparison with the control group ($P < 0.05$). The present study suggests that 100 ppm oral doses of lead acetate II might have strong destructive effects on femur histology and osteocalcin expression.

Keywords: Lead acetate, bone, osteoblast, alizarin red S, osteocalcin

Lead is one of the deleterious metals with toxic effects on animals' health even at low concentrations in drinking water. According to the world health organization (WHO) the standard amount of lead in water is 10 ppm, but in many regions higher amounts of lead may be encountered. Among factors causing water pollution are human activities, and particularly industrial ones that produce lead components near underground aquifer layers (1-2). At doses higher than standard, many tissues including brain, liver, kidney, reproductive system, cartilage, and bone are damaged. Neuromuscular disorders, renal failure, and high

blood pressure might be induced by lead (3-4). Lead may be absorbed through different routes such as breathing, skin, and mouth. Through oral route, it can easily enter into the blood and consequently soft tissues and bone. Also, long-term toxicity is caused by lead accumulation in bone. Lead is able to pass across placenta, and at high doses can exert teratogenic effects and mental retardation in embryo. Factors such as chemical composition, dose, route, and duration of lead exposure can variously affect the body (3, 5).

Osteocytes are derived from osteoblasts, although many underlying mechanisms still remain unknown.

*Correspondence: Department of Basic Sciences, Veterinary Medicine faculty, Tabriz University, Tabriz, Iran.
E-mail: dvm.milad73@yahoo.com

Osteoblasts can differentiate into osteocytes, inactive osteoblasts, and periosteum cells, however, some of them may undergo apoptosis (2, 6). Osteocalcin is a non-collagenous protein that is released from osteoblasts into the extracellular matrix, and contributes to the maintenance of bone. During osteocalcin release, the fat and energy metabolism of osteoblasts are controlled by the endocrine activity. Also, osteocytes differentiation is controlled by the activity of osteoblasts. Osteocytes are osteoblasts that are buried in the bone matrix, and possess extensive dendritic processes that are able to communicate with each other (6-7). Dendritic processes have mechanical roles, and participate in biochemical responses controlling osteoblasts and osteoclasts activities. Large, multi-nuclear cells on the surface of trabecular bone that are called Howship's lacunae or resorption cavities serve for bone resorption and remodeling. Osteoclasts originate from monocyte stem cells lineage, and act like circulating macrophages. After bone fracture, osteoclasts leave their compartment (4, 8-9).

The outer surface of all bones, except on joints of long bones, are covered by periosteum which is a dense irregular connective tissue that contains fibroblasts in its outer fibrous layer, and progenitor cells developing into osteoblast in its inner cambium layer. These osteoblasts are responsible for width growth of long bones, and general size acquisition of other types of bones. After bone fracture, progenitor cells of periosteum become indispensable for healing by differentiating into osteoblasts. Collagenous fibers called Sharpey's fibers cause bone attachment to periosteum muscles and tendons (11).

Osteoporosis is a disease affecting many people around the world. It is specified by low bone mineral density, and destruction of bone tissue leading to increased risk of fracture. The fracture can occur in hip, spinal cord, wrist, femur, etc. There are common reasons to cause osteoporosis such as aging, diet, physical inactivity, smoking, intestinal dysbiosis, heavy metals, etc. (12-13).

Osteocalcin as a non-collagenous protein in bone and teeth, is produced by osteoblasts and participates in metabolic regulation of the body and bones. The level of osteocalcin is a marker of bone metabolism, and is a specific index for the assessment of bone diseases (14). In this research, we focused on the 100 ppm dose of lead as a predisposing factor for osteoporosis. The aim of this study was to investigate the destructive effects of lead acetate II on the bone by studying the expression level of osteocalcin gene, and histological properties of bone.

Materials and methods

Animals and housing

Twenty male Wistar rats with approximate weight of 500 g were bought from Razi Vaccine and Serum Research Institute of Mashhad. All rats were kept under standard condition including 12:12 h interval light/dark cycle at 25 °C in standard cages. The rats were randomly divided into two groups. The test group was fed with distilled water containing lead acetate II at the dose of 100 ppm along with libitum feed, while the control group was fed with distilled water with libitum feed during 2 months. Animals were treated according to the institutional guidelines for animal care and use.

Histological studies

After two months the rats were anesthetized and their femurs were removed. Then muscle and epiphysis were eliminated. All femur bones were fixed in 10% formalin. After decalcification with ethylenediaminetetraacetic acid (EDTA) as chelating agent, they were passed through successive stages of dehydration (using 50%, 70%, and 90% alcohol, respectively to replace the water with alcohol), clearing with xylene, infiltration, and paraffin embedding (15). The samples were sectioned into 4 µm thickness using a Leitz microtome, and were mounted. The staining stages included deparaffinization and hydrating with 70% alcohol, rapid washing with deionized distilled water, addition of Alizarin red S solution pH of 4.1

to 4.3 for 5 min (orange-red coloration under the microscope demonstrated bone mineralization), shaking off dye surplus and blotting sections, dehydrating in acetone (20 dips). Then slides were treated with acetone-xylene (20 dips). After xylene clearing the slides were mounted. In addition, Hematoxylin and Eosin staining was performed.

The sections were evaluated in terms of mineralization and bone density, density of osteoblasts, and diameter of bone marrow (the inner diameter of the femur). Color intensity of Alizarin red S demonstrating bone mineralization, was evaluated based on Gong table (16).

RNA extraction

QualiNuclei® Total RNA Extraction Kit (CNEK-R1799H, Creative Bioarray, USA) was used for extracting RNA according to manufacturer's instructions. Isopropanol and chloroform were used for RNA sedimentation after cells lysis. Next, ethanol 70% was used for RNA washing and RNA was dissolved in water.

Synthesis of the cDNA and Real time PCR

Synthesis of cDNA was as described previously (14) and using cDNA synthesis kit (Revert Aid H Minus first standard cDNA synthesis kit-Fermentas), and according to manufacturer's instructions. Briefly, 10 µl of RNA was incubated at 65 °C for 5 to 10 min. Next, 3 µl of 3X reaction buffer, 0.2 µg of reverse and forward primers of osteocalcin gene, 0.5 µl reverse transcriptase

enzyme, 10 µM dNTPs, 3 µl MgCl₂ 25 mM were added, respectively. This solution was incubated for 10 min at 25 °C and then for 60 min at 42 °C. Finally, in order to stop the reaction, the solution was exposed at 70 °C for 10 min. The synthesized cDNA was kept at -80 °C. Real time PCR was performed using QuantiTect SYBER Green PCR kit in a real time instrument (Bio-Rad, USA). The sequences of primers and amplification conditions were described previously. Finally, the expression levels of osteocalcin gene were calculated in comparison with *GAPDH* expression, and according to the Livak technique (with the $2^{-\Delta\Delta C_t}$ formula).

Statistical analysis

In this research, statistical analyzes were performed with SPSS 21 (SPSS Inc. Chicago IL. USA). Kruskal wallis and T-test were used for comparing the intensity of mineralization, and bone marrow diameter between test and control groups. P values < 0.05 were considered as statistically significant.

Results

Histopathological changes were observed in tested group

Based on Gong table, the median of color intensity (alizarin red S) was 4.7 and 2.3 in case and control groups, respectively (P < 0.004) (figure 1 and figure 2). Osteoblasts density was lower in cases in comparison with controls (figure 3). As shown in

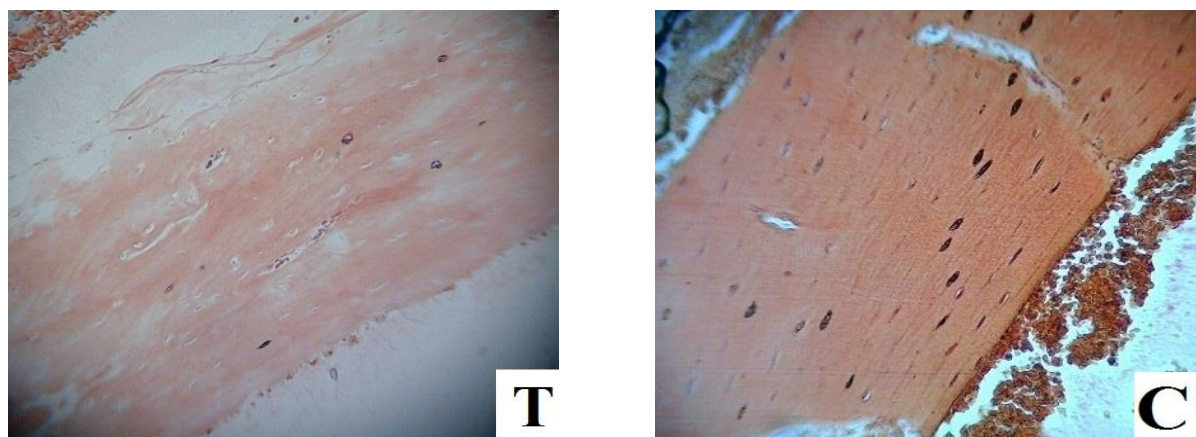


Figure 1. Photomicrograph of bone mineralization intensity. The intensity of bone mineralization was evaluated by comparing the intensity of red color after staining with alizarin red S, (x 100). T: tested group; C: control group.

figure 3 some osteoblasts were destructed. Also, the inner diameter of the femur was higher in cases in comparison with controls ($P < 0.004$) (figure 4). The median of the inner diameter of femur in the case group was 1500 μm , but in the control group was 1100 μm (figure 5).

The expression level of osteocalcin gene

The results of Real time PCR demonstrated that lead decreased the expression of the osteocalcin gene in comparison with the control group ($P < 0.05$).

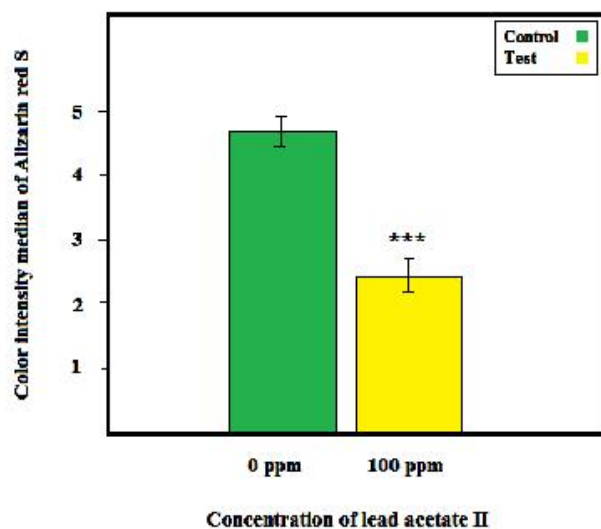


Figure 2. Comparison of median of alizarin red S color intensity between tested and control groups. ($n = 20$, ***: $P < 0.004$).

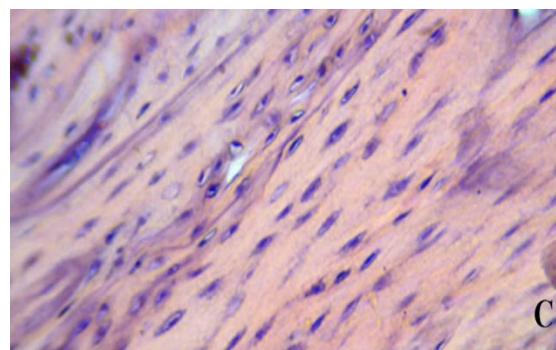
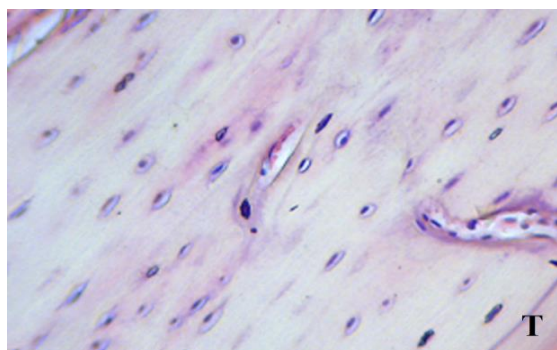


Figure 3. Rat osteoblasts density. T: tested group; C: control group. Hematoxylin-Eosin staining revealed that the density of osteoblasts was lower in cases in comparison to control group; ($\times 400$).

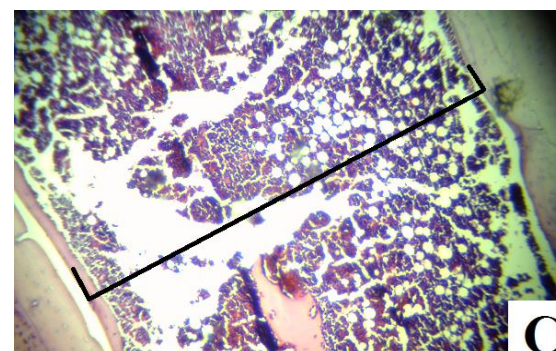
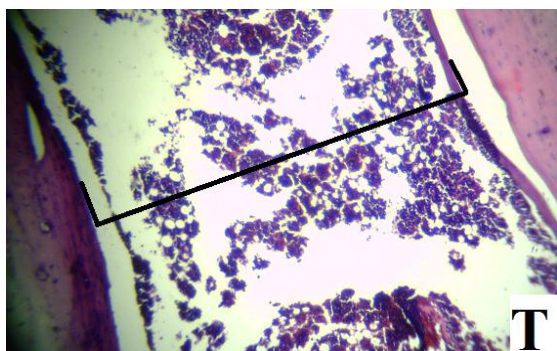


Figure 4. Femur bone marrow diameter. T: tested group; C: control group. Hematoxylin-Eosin staining; ($\times 100$).

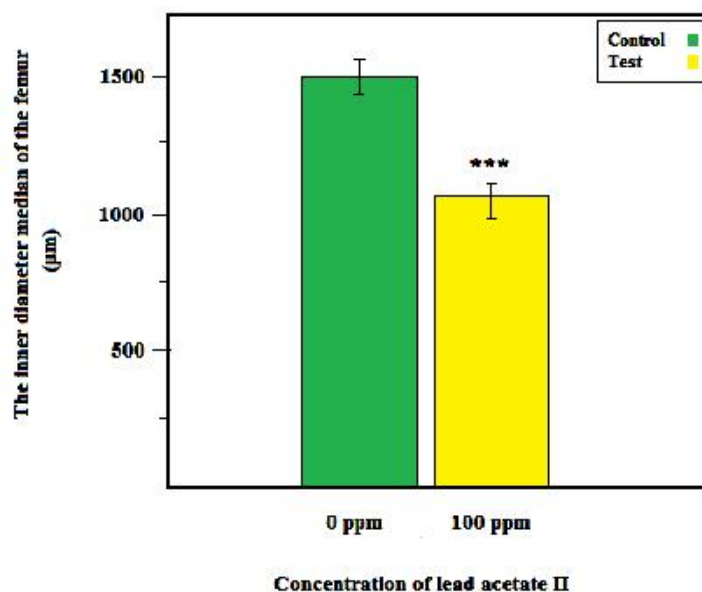


Figure 5. Comparison of the median of inner diameter of the femur between case and control groups (n =20, ***: P < 0.004).

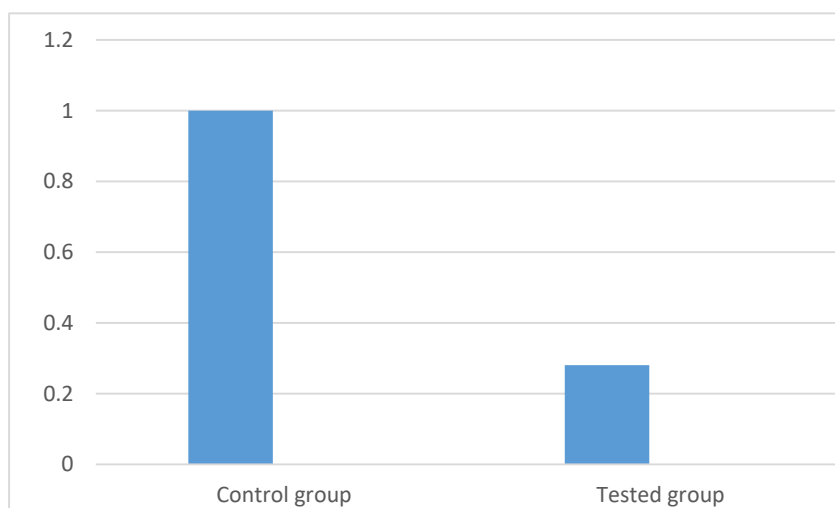


Figure 6. Relative expression level of osteocalcin gene. The expression of osteocalcin gene decreased significantly in tested group in comparison with control group (P < 0.05).

Discussion

One of the most important factors in etiology of osteoporosis is high concentration of lead. Osteoporosis is related to reduced mineralization, and alteration of bone turnover characteristics. Lead is a serious factor involved in fracture illness that raises with aging. The half-life of this heavy metal increases with enhancement of its amount. Bone mass decrease is associated with decreased osteoblasts number, causing bone formation defect. Lead changes bone remodeling by reducing the formation of new mineralization that is related to

decreased calcium levels (2, 17-18). Lead acetate II can produce focal areas of sclerosis, fibrosis, and coarse reticular fibers along with minimal cells. Increasing lead in the blood, soft tissue, and consequently in bone, causes calcium decrease. In hydroxyapatite, calcium is replaced by lead in the form of lead phosphate deposition in combination with the bone (19-20). Lead causes apoptosis in osteoblasts due to the degeneration of many bone specific proteins. In other words, high lead concentration increases the risk of bone fracture due to the change of bone microenvironment. Also,

destruction of bone marrow space by lead acetate II may be observed. Lead acetate II causes significant reduction in carbonyl protein content and significant increase in glutathione levels in bone marrow. However, all mechanisms of these bone structure changes are not clear (2).

Rat trabecular bone is decreased by lead along with appearance of irregularities in the cavity of primary bone marrow. Also, osteoblasts show fewer organelles with focal cytolysis. Morphological investigations indicated that lead inhibited growth plate development. Thus, femoral bone is one of the key target tissues for evaluating the effect of lead on skeleton development (3, 21). It has been demonstrated that lead decreased axial bone development and the mass of bone along with decreasing the number of osteoblasts and osteocytes. This is due to the resorption enhancement caused by lead accumulation, as measured by densitometry (5, 23). Lead may combine irreversibly to many bone proteins like osteocalcin, and they become therefore non-functional. Decrease of osteoblast density and mineralization can be attributed to high doses of lead. Chromosomal aberrations and micronuclei alterations are generated by lead accumulation *in vivo* in bone marrow. Lead acetate II was shown to induce cell toxicity and apoptosis in mesenchymal stem cells in a dose dependent manner by causing the overexpression of Bax, caspase 9 and caspase 3, and creating DNA damage as revealed by MTT assay. It also reduced bone cells density along with decreasing haversian systems (22-23). Some changes like mineralization and osteoblast density were evident in this study, but some changes especially thickness of periosteum and the diameter of the bone were not investigated. Since the concentration of lead was ten-fold higher than WHO standard, the histological changes of bone can be attributed to high amount of this element, and its resorption. Regarding the decreased level of osteocalcin gene and the important role of this gene in bone metabolism, we could relate the disturbances of bone as the result of the effect of

exposure on this gene. Also, because of calcium substitution by lead, calcium evacuation will happen after lead exposure.

The present study showed that lead acetate II induced some changes and main signs in bone histology which include mineralization reduction, decreased number of osteoblasts, and diminished diameter of bone marrow. Also, it decreased the expression level of osteocalcin gene as a main regulator of bone metabolism.

Conflict of interest

The authors declared no conflict of interest.

References

1. Gonzalez-Riola J, Hernandez E R, Escibano A, et al. Effect of lead on bone and cartilage in sexually mature rats: a morphometric and histomorphometry study. *Environ Res.* 1997;74:91-3.
2. Ma Y, Fu D, Liu Z. Effect of lead on apoptosis in cultured rat primary osteoblasts. *Toxicol Ind Health.* 2012;28:136-46.
3. Brito J A, Costa I M, Am E S, et al. Changes in bone Pb accumulation: cause and effect of altered bone turnover. *Bone.* 2014;64:228-34.
4. Struijs P A, Poolman R W, Bhandari M. Infected nonunion of the long bones. *J Orthop Trauma.* 2007;21:507-11.
5. Suleman M, Khan A A, Hussain Z, et al. Effect of lead acetate administered orally at different dosage levels in broiler chicks. *Afr J Environ Sci Tech.* 2011;5:1017-26.
6. Augat P, Margevicius K, Simon J, et al. Local tissue properties in bone healing: influence of size and stability of the osteotomy gap. *J Orthop Res.* 1998;16:475-81.
7. Chen X, Zhang L, Yang X, et al. Micronutrients-incorporated calcium phosphate particles with protective effect on osteoporotic bone tissue. *J Nutr Health Aging.* 2013;17:426-33.
8. Gomez-Barrena E, Rosset P, Lozano D, et al. Bone fracture healing: cell therapy in delayed unions and nonunions. *Bone.* 2015;70:93-101.
9. Schindeler A, McDonald M M, Bokko P, et al. Bone remodeling during fracture repair: The cellular picture. *Semin Cell Dev Biol.* 2008;19:459-66.
10. Zhang L, Richardson M, Mendis P. Role of chemical and mechanical stimuli in mediating bone fracture healing. *Clin Exp Pharmacol Physiol.* 2012;39:706-10.

11. Xing Q, Qian Z, Kannan B, et al. Osteogenic Differentiation Evaluation of an Engineered Extracellular Matrix Based Tissue Sheet for Potential Periosteum Replacement. *ACS Appl Mater Interfaces*. 2015;7:23239-47.
12. Prentice A. Diet, nutrition and the prevention of osteoporosis. *Public Health Nutr*. 2004;7:227-43.
13. Todd J A and Robinson R J. Osteoporosis and exercise. *Postgrad Med J*. 2003;79:320-3.
14. Rafiei H and Ashrafzadeh M. Expression of Collagen Type II and Osteocalcin Genes in Mesenchymal Stem Cells from Rats Treated with Lead acetate II. *Iranian Journal of Toxicology*. 2018;12:35-40.
15. Rafiei H, Shariati M, Khayatzadeh J, et al. Effects of Oral Dosage of Lead Acetate II on Osteocalcin Gene Expression in Rat Mesenchymal Stem Cells. *Rep Biochem Mol Biol*. 2018;6:131.
16. Gong H, Ye W, Freddo T F, et al. Hyaluronic acid in the normal and glaucomatous optic nerve. *Exp Eye Res*. 1997;64:587-95.
17. Alvarez-Lloret P, Rodriguez-Navarro A B, Romanek C S, et al. Effects of lead shot ingestion on bone mineralization in a population of red-legged partridge (*Alectoris rufa*). *Sci Total Environ*. 2014;466-467:34-9.
18. Deschaseaux F, Sensebe L, Heymann D. Mechanisms of bone repair and regeneration. *Trends Mol Med*. 2009;15:417-29.
19. Aboul-Ela E I. The protective effect of calcium against genotoxicity of lead acetate administration on bone marrow and spermatocyte cells of mice in vivo. *Mutat Res*. 2002;516:1-9.
20. Rodriguez-Estival J, Alvarez-Lloret P, Rodriguez-Navarro A B, et al. Chronic effects of lead (Pb) on bone properties in red deer and wild boar: relationship with vitamins A and D3. *Environ Pollut*. 2013;174:142-9.
21. Lu H, Yuan G, Yin Z, et al. Effects of subchronic exposure to lead acetate and cadmium chloride on rat's bone: Ca and Pi contents, bone density, and histopathological evaluation. *Int J Clin Exp Pathol*. 2014;7:640-7.
22. Tham C S, Chakravarthi S, Haleagrahara N, et al. Morphological study of bone marrow to assess the effects of lead acetate on haemopoiesis and aplasia and the ameliorating role of Carica papaya extract. *Exp Ther Med*. 2013;5:648-52.
23. Sharifi A M, Ghazanfari R, Tekiyehmaroof N, et al. Investigating the effect of lead acetate on rat bone marrow-derived mesenchymal stem cells toxicity: role of apoptosis. *Toxicol Mech Methods*. 2011;21:225-30.