

## A case of chronic Budd-Chiari syndrome in 24 years old man complicating secondary antiphospholipid syndrome in association with autoimmune hepatitis

Fariborz Mansour-Ghanaei<sup>1A</sup>, Iman Soufi Afshar<sup>2A</sup>, Afshin Shafaghi<sup>2\*</sup>, Farahnaz Joukar<sup>1</sup>, Masoud Baghaei<sup>2</sup>, Saba Fakhrieh Asl<sup>2</sup>, Mahsa Mohtasham<sup>2</sup>, Ali Akbar Samadani<sup>3</sup>

1- GI Cancer Screening and Prevention Research Center, Guilan University of Medical Sciences, Rasht, Iran

2- Gastrointestinal and Liver Diseases Research Center, Guilan University of Medical Sciences, Rasht, Iran.

3- Healthy Ageing Research Center, Neyshabur University of Medical Sciences, Neyshabur, Iran.

Submitted 8 Dec 2019; Accepted 11 Jan 2020; Published 2 Feb 2020

In Budd-chiari syndrome (BCS), obstruction of the hepatic venous outflow tract occurs at a site from the small hepatic veins to the junction of the inferior vena cava with the right atrium, and this syndrome can have various causes. Remarkably, BCS can be classified as primary or secondary; primary BCS is caused by venous thrombus or phlebitis, while secondary BCS is due to venous compression or invasion of an extrinsic lesion, such as a tumor, abscess, or cyst. Antiphospholipid syndrome (APS) is an acquired cause of primary BCS. A 24-year-old man, with complaints of abdominal pain, abdominal anorexia starting three months earlier, was admitted to Rasht Razi Hospital. The patient's pain did not relate to feeding, defecation and positioning. The patient had nausea and vomiting half an hour after feeding. He also mentioned a weight loss of about 5 kg and also, had blood pressure. He had no history of smoking, alcohol and opiums and had not any specific illness in his family. Due to abdominal distension and hepatosplenomegaly, an ultrasound examination was performed for the patient, ascites were diagnosed and the patient was subjected to ascites fluid paracentesis. High gradient of albumin and low protein were reported. The patient was first examined for cardiac examination and heart echocardiography and other examinations were reported as normal. A CT scan of the abdomen, pelvic and doppler ultrasonography was performed that showed ascites and enlargement of the caudate lobe. The findings were compatible with BCS. The diagnosis of BCS was confirmed by a hemodynamic study, and further investigation for the cause of BCS was positive. Antinuclear antibodies, deficiency of protein C and S were detected. LA was not present and aCL (IgM, IgG) were positive. Moreover, serology was negative for hepatitis B or C and serum protein electrophoresis was demonstrated high levels of gamma globulin. We concluded that the patient had chronic BCS secondary to APS in association with autoimmune hepatitis. Ultimately, the patient was treated with prednisolone 60 mg/daily and warfarin, and was referred to a transplantation-equipped center for liver transplantation. In conclusion, BCS, although infrequent, is not a rare complication in patients with APS and may be the first clinical manifestation of this syndrome. In this patient, BCS caused by the initiation of AIH and secondary APS.

**Keywords:** Budd-Chiari syndrome (BCS), antiphospholipid antibodies (aPL), Antiphospholipid syndrome (APS), Autoimmune hepatitis (AIH)

**B**udd-Chiari syndrome (BCS) is a rare condition induced by thrombotic or non-thrombotic

obstruction of the hepatic venous outflow which occurs in 1/100 000 of the general population

\*Correspondence: Gastrointestinal and Liver Diseases Research Center, Guilan University of Medical Sciences, Rasht, Iran.

E-mail: drafshinshafaghi@gmail.com

A. These authors have equal contributions

worldwide (1, 2). Patients may present with acute signs and symptoms of abdominal pain, ascites and hepatomegaly or more chronic symptoms related to long-standing portal hypertension (3). In this way, BCS is further classified as being primary or secondary, depending on the exact nature of the hepatic venous outflow obstruction. Conspicuously, when flow is obstructed by compression or invasion of a lesion outside the hepatic venous outflow track, it is regarded as being secondary BCS; for examples, it is include: malignant and cystic extrinsic obstruction. If flow is obstructed due to an endoluminal aberration, then it is classified as being primary BCS. Remarkably, the most common cause of primary BCS is thrombosis, polycythemia vera, essential thrombocythemia, paroxysmal nocturnal hemoglobinuria, antithrombin, protein C and protein S deficiency, resistance to activated protein C, factor V Leiden, G20210A factor II gene mutation, use of oral contraceptives, pregnancy and postpartum state although geographical differences exist with idiopathic membranous obstructions (webs) being prevalent in Asia (1, 4-7). In some studies, a relationship between BCS and elevated levels of antiphospholipid antibodies (aPL) has been suggested (4, 8). The patient of autoantibodies directed to a complex of phospholipids and proteins and comprise Lopus anticoagulant (LA) and anticardiolipin antibodies (aCL) (4). Several studies have shown that patients with aPL are prone to repeated episodes of thrombosis and spontaneous fetal losses. The association of aPL with these clinical events has been termed the antiphospholipid syndrome (APS) (9), and it is considered “primary” if not associated with other underlying disease or “secondary” if it appears in association with other autoimmune disorders, Such as autoimmune hepatitis (AIH), but an association between these two conditions has rarely been reported (10). In this report, we describe a male patient with chronic BCS complicating APS. In addition, we reviewed the laboratory findings over the past two years that are probably the cause of secondary APS was

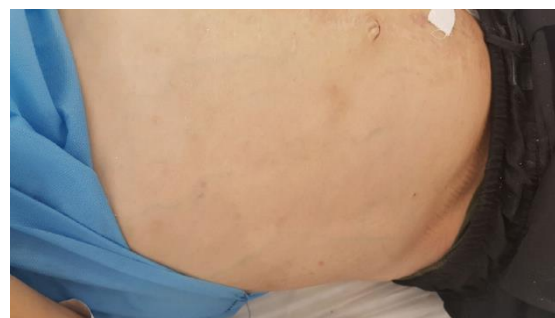AIH disease.

### Case Report

The 24-year-old patient, who had progressive icterus abdominal pain and distension since last three months (Figure1). Also, he had abdominal distension since one month ago. The patient had continual abdominal pain and did not have any radiation. Abdominal pain had no association with feeding and defecation and was not positional. Occasionally, he mentioned nausea and vomiting alongside with abdominal pain, which was about half an hour after feeding. In addition, dyspnea was noted following abdominal distension. The patient mentioned the history of high blood pressure since adolescence and had a history of appendectomy at the age of 10 years. The patient did not have a family history of illness. Moreover, vaccination was completely performed and was taken twice Lozartan 25 mg/day.

### Examinations

The conjunctiva was not pale and sclera was not icteric, the kayser fleischer was not seen and Jugular vein pressure and lung auscultation was normal, also, the sound of the heart was normal, without murmur and extra sound. During the inspection of the abdomen, it was symmetric with distention and umbilical hernia and the cuffs were prominent (Figure1).The intestinal sounds were normal, mild tenderness was in periumbelical and the rebound tenderness has been negative. The patient had clubbing in his hands and feet (Figure2). Other clinical manifestations are listed in the table1.



**Figure 1.** Ascites, caput medusa and umbilical hernia.

**Table 1.** Clinical manifestation of the patient

Night sweating		Pitting Edema in lower limbs	
Fever	Negative	Petechia and Purpura	Negative
Melena		Cyanosis	
Rectal bleeding		Palmar erythema	
Diarrhea		Skin lesion	
Constipation		Clubbing	
DM	Positive	Loss of appetite	Positive
Bilateral temporal atrophy		Early satiety	
IHD		Paler	
LAP		Shifting dullness	
Icterus		Caput medusa	
HTN			

## Experiments

Initial tests were requested for the patient and an

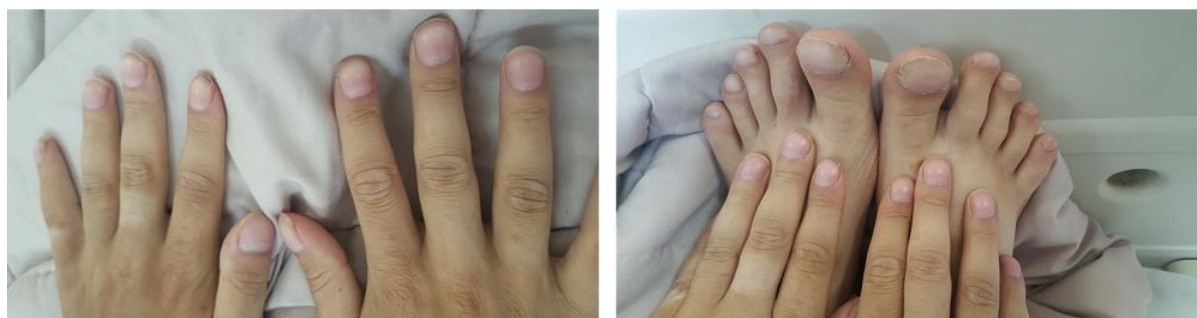ultrasound was performed for the patient. The ultrasound revealed an increase in the size of the

**Table 2.** Laboratory findings of patient in 2017

Biochemistry		Immunology	
Albumin	3.8	Anti-nuclear antibody (ANA)	H 32
AST	30	Immune Elect	
ALT	11	IgG	H 21.76
Alkaline phosphatase (ALP)	H 359	IgA	2.45
Total Bilirubin	H 2.4	IgM	1.08
Direct Bilirubin	H 0.9	ANCA	
FBS	71	P-ANCA (Anti MPO)	0.1
BUN	L 6	C-ANCA (Anti PR3)	0.1
Gamma. G.T	H 105		
Special Biochemistry		Immunoassays	
Ceruloplasmin serum	40.6	Anti-Liver Kidney microsomal	Negative
Albumin	H 47.1		
ALPHA1	H 5.0		
ALPHA2	9.0		
BETA1	6.2	Anti-nuclear antibody (ANA)	6
BETA2	4.9		
GAMMA	H 27.8		
Albumin/globulins	0.89	Anti-Smooth Muscle Ab	Negative
IgG	H 2497		

**Table 3.** Laboratory findings of patient in 2019

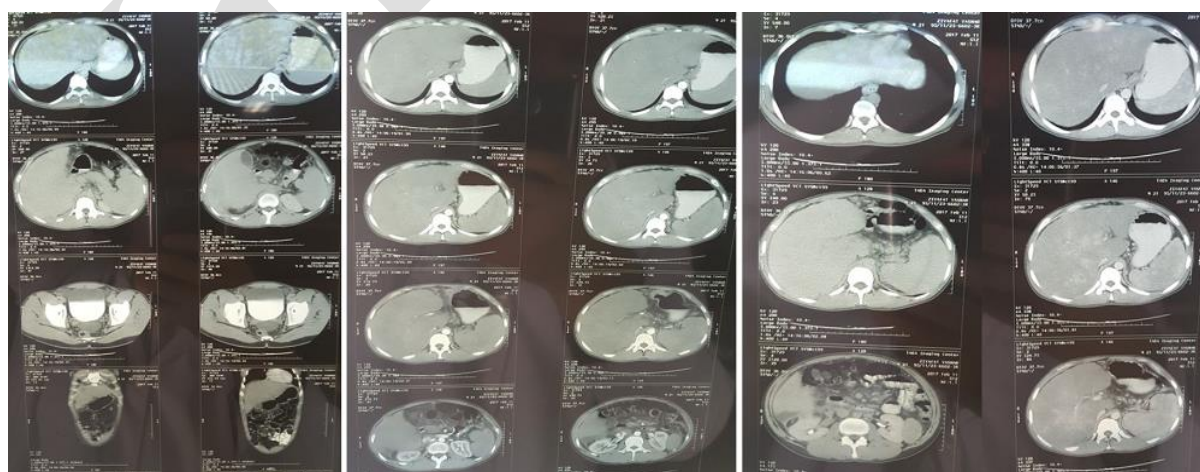
Hematology/ Biochemistry		Coagulation	
WBC	6500	PT	H 19.1
RBC	L 3.79	PTT	H 54
Hemoglobin	L 9.1	INR	2.1
Hematocrit	L 29.8	Factor V-leiden	340
Platelet	L 124000	Prothrombin	Normal
MCV	L 72.4	Lupus Anti Coagulant	Negative
MCH	L 23.7	Protein C Assay	L 22
MCHC	L 30.2	Protein C Assay	L 38
RDW	H 13.1	Special Biochemist-Tumor Markers	
ESR	98	Serum Homocysteine	10
CRP	Negative	Beta2-microglobulin	H 3.1
Anisocytosis	Positive	Auto Immune Diseases	
Hypochromia	Positive	Anti Cardiolipin (IgG)	H 1636*
Poikilocytosis	Positive	Anti Cardiolipin (IgM)	H 32*
Schistocytosis	Positive	Serology	
Neutrophil	76.7%	Anti-nuclear antibody (ANA) (IF)	H 1.160
Lymphocyte	13.6%	Immunology	
Monocyte	6.2%	Liver Kidney microsomal Ab	Negative
glucose	104	Delivery	
protein	43		
Albumin	19	soluble <u>liver antigen</u> (SLA) IgG Antibody	2.2
ALT	H 51	BUN	6
AST	H 80	Cr	0.7
ALP	H 352	K	3.6
LDH	H 462	Na	139
FBS	95	Fe	61
Amylase	37	Ferritin	45
Lipase	22	TSH	1.4
BILI T	H 1.9	FT4	0.9
Gamma GT	H 105	Vitamin D	1.1
TIBC	299	Hbs Ag	Negative
TS	20%	HCV Ab	Negative
Urine volume(24hrs)	1250	Fluid A.D.A	L 3
Urine creatinine(24hrs)	1.3	FC	2
Urine copper(24hrs)	32		



**Figure 2.** Clubbing is a deformity of the finger or toe nails.

liver (liver span: 196mm) and spleen (spleen span: 166\*72mm), and no evidence of thrombosis in the liver and portal veins was evident. Correspondingly, free fluid was seen at moderate to severe level in the abdomen and pelvic, subsequently the ascites were detected and therapeutic tap was performed that the high SAAG (1.7mg/dl) and low protein were reported. Dynamic liver CT showed that the peripheral part of the liver had mild hypoattenuation, which is compatible with reverse portal venous blood flow. The hepatic veins could not be well seen. Also, enlargement of the caudate lobe is noted. Portal vein is normal in course and caliber without clot formation or thrombosis (Figure 3). The findings of CT scan reveal enlarged liver and spleen with evidence of Budd-Chiari syndrome. The cardiac output was 55% and the pulmonary artery pressure was 35-40 mmHg, a little fluid was seen in the pericardium. Considering the possibility of BCS,

abdominal doppler ultrasonography was performed. Hepatic veins were patent with no visible flow by color doppler sonographic study indicative of BCS. Consequently, additional tests were carried out to determine the cause of BCS. Finally, due to the positive anti-nuclear antibody (ANA) and aCL, BCS complicated with APS was diagnosed. We looked at the cause of APS by examining laboratory findings from two years ago (Table 2, 3). Biochemistry tests showed elevation of liver enzymes and IgG. ANA was positive, while Liver Kidney Microsomal Antibody (LKM) and Smooth Muscle Antibody (SMA), HCV Antibody and HCV Antigen were negative. So it can be guessed that this patient was probably an autoimmune hepatitis in the past that has been the cause of the secondary APS. The patient was treated with prednisolone and warfarin was referred to the transplant center for liver transplantation.



**Figure 3.** Multidetector spiral CT scan of abdomen and pelvic with IV and oral contrast with coronal and dynamic liver CT images acquisition was performed which showed liver is mildly enlarged with heterogeneous parenchyma. The peripheral part of the liver showed mild hypoattenuation, which is compatible with reverse portal venous blood flow. The hepatic veins could not be well seen. Also, enlargement of the caudate lobe is noted.

**Table 4.** Elements from the patient's history and laboratory findings attributed to AIH the APS and the BCS

Symptoms/signs	Laboratory	Findings
<b>AH</b>		
Hepatomegaly	ALT	H
	AST	H
	ALP	H
	GGt	H
	PT	H
	PTT	H
	Billirubin	H
	$\gamma$ -globulin	H
	$\alpha$ -globulin	H
	IgG	H
	HBs Ag	Negative
	ACV Ab	Negative
	ANA	Positive
<b>APS</b>		
Nausea	PLT	L
	PT	H
Vomiting	PTT	H
	Protein C	L
Dyspnea	Protein S	L
	aCL	Positive
	Beta2-macroglobulin	Positive
<b>BCS</b>		
Abdominal Pain loss of appetite	ALT	H
Tenderness	AST	H
High Blood Pressure Hepatomegaly	ALP	H
splenomegaly	GGt	H
Ascites	PT	H
Mild Hypoattenuation in liver Portal veins with absent and reversed flow	PTT	H
Enlargement of coadate lobe	Billirubin	H

H, increased; L, decreased; ALT, Alanine aminotransferase; AST, Aspartate transaminase; ALP, Alkaline phosphatase; GGT, Gamma-glutamyl transferase; PLT, platelets; PT, prothrombin time; PTT, Partial thromboplastin time; ANA, antinuclear antibodies; aCL, Anti Cardiolipin. Patient history (AH, APS, BCS): Abdominal pain and Distension, dyspnea, Nausea and vomiting, weight loss, early satiety, loss of appetite, High Blood Pressure, Appendectomy mild tenderness in periumbelical, shifting dullness and caput medusa, clubbing.



## Discussion

BCS is a potentially life-threatening complication in APS (11). BCS associated with APS is usually subacute or chronic, while acute BCS is rare and is reported to have a poor out-come (12). In this patient, three common presenting features of BCS (abdominal pain (61%), ascites

(83%), and hepatomegaly (67%), was reported but the symptoms of BCS vary with its clinical presentation. For diagnosis of BCS, obstruction of hepatic venous outflow should be confirmed by invasive or noninvasive tests. Martens and Nevens reported that Doppler ultrasonography has a higher sensitivity and specificity for diagnosis of BCS among noninvasive tests (13). In our patient, the peripheral part of the liver showed mild hypoattenuation, which is compatible with reverse portal venous blood flow. The hepatic veins could not see well and they are patent with no visible flow. Additionally, he had elevation of hepatic enzymes and bilirubin. CT scan had previously revealed enlargement of liver and spleen with multiple lymph nodes in the splenic hilum. Contradictory, abdominal aorta and IVC showed normal course and caliber without paraaortic lymph adenopathy. Ascites or hepatic necrosis is mild and collateral circulation forms. Chronic BCS is characterized by portal hypertension and can be complicated by splenomegaly and esophageal varices. We diagnosed Chronic BCS is characterized by findings of abdominal ultrasonography. aPL may be encountered in several conditions including autoimmune diseases, infections, malignancies and drug abuse (14). They can also be found in 2±6.5% of healthy individuals, without risk of thrombosis (15). Clinical manifestations and laboratory findings of the APS include fetal loss and arterial or venous thrombosis, thrombocytopenia and the presence of aPL (10). In our patient, fetal loss, ANA and aCL (IgM and IgG) were positive. Despite the association of the APS with AIH is extremely rare (4).

## Conclusion

We concluded that in this patient the cause of the secondary APS was AIH. Other indications from the patients' history, clinical symptoms and signs, as well as laboratory findings, pointing to the diagnosis of BCS, APS and AIH are summarized in Table 4. Secondary APS may rarely present in association with autoimmune hepatitis. Therefore, patients with autoimmune hepatitis and thrombosis or fetal loss should be tested for the APS. To our knowledge BCS following the initiation of AIH that the lack of treatment created a secondary APS.

## Compliance with Ethical Standards

(In case of Funding) Funding: This study was funded by the Gastrointestinal and Liver Diseases Research Center, Guilan University of Medical Sciences, Rasht, Iran (grant number 1397).

Please add the following just before the References:

## Ethical approval

All procedures performed in studies involving human participants were in accordance with the ethical standards of the institutional and/or national research committee and with the 1964 Helsinki declaration and its later amendments or comparable ethical standards.

## Informed consent

This project was done with the agreement and informed consent of all the patients.

## Conflict of interest

The authors declared no conflict of interest.

## References

- 1- Aydinli M, Bayraktar Y. Budd-Chiari syndrome: etiology, pathogenesis and diagnosis. *World J Gastroenterol*. 2007;13(19):2693-6.
- 2- Grus T, Lambert L, Grusova G, Banerjee R, Burgetova A. Budd-Chiari Syndrome. *Prague Med Rep*. 2017;118(2-3):69-80.
- 3- Valla DC. Primary Budd-Chiari syndrome. *J Hepatol*. 2009;50(1):195-203.
- 4- Espinosa G, Font J, Garcia-Pagan JC, Tassies D, Reverter JC, Gaig C, et al. Budd-Chiari syndrome secondary to

- antiphospholipid syndrome: clinical and immunologic characteristics of 43 patients. *Medicine (Baltimore)*. 2001;80(6):345-54.
- 5- Plessier A, Valla DC. Budd-Chiari syndrome. *Semin Liver Dis*. 2008;28(3):259-69.
- 6- Al Himali SH, Al Osaimi AM, Dahab ST, Khuroo MS, Al Ashgar HI. Budd Chiari syndrome: experience at King Faisal Specialist Hospital and Research Centre, Riyadh, Saudi Arabia. *Saudi J Gastroenterol*. 2003;9(1):11-4.
- 7- De BK, De KK, Sen S, Biswas PK, Das TK, Das S, et al. Etiology based prevalence of Budd-Chiari syndrome in eastern India. *J Assoc Physicians India*. 2000;48(8):800-3.
- 8- Chinen N, Koyama Y, Sato S, Suzuki Y. A Case of Acute Budd-Chiari Syndrome Complicating Primary Antiphospholipid Syndrome Presenting as Acute Abdomen and Responding to Tight Anticoagulant Therapy. *Case Rep Rheumatol*. 2016;2016:9565427.
- 9- Schreiber K, Sciascia S, de Groot PG, Devreese K, Jacobsen S, Ruiz-Irastorza G, et al. Antiphospholipid syndrome. *Nat Rev Dis Primers*. 2018;4:17103.
- 10- Dourakis SP, Michael AE, Papanikolaou IS, Nomikou E, Thalassinou P, Hadziyannis SJ. Autoimmune hepatitis associated with the antiphospholipid syndrome. *Eur J Gastroenterol Hepatol*. 2001;13(5):591-3.
- 11- Rajesh S, Mukund A, Arora A. Imaging Diagnosis of Splanchnic Venous Thrombosis. *Gastroenterol Res Pract*. 2015;2015:101029.
- 12- Uthman I, Khamashta M. The abdominal manifestations of the antiphospholipid syndrome. *Rheumatology (Oxford)*. 2007;46(11):1641-7.
- 13- Martens P, Nevens F. Budd-Chiari syndrome. *United European Gastroenterol J*. 2015;3(6):489-500.
- 14- Devine DV, Brigden ML. The antiphospholipid syndrome: when does the presence of antiphospholipid antibodies require therapy? *Postgrad Med*. 1996;99(6):105-8, 13-25.
- 15- Vila P, Hernandez MC, Lopez-Fernandez MF, Batlle J. Prevalence, follow-up and clinical significance of the anticardiolipin antibodies in normal subjects. *Thromb Haemost*. 1994;72(2):209-13.