IBBJ

Spring 2023, Vol 9, No 2

Original Article

The wound healing effect of fish scales isolated collagen sponge along with Eisenia foetida glycolipoprotein extract (G-90) in foot ulcer of diabetic rat

Maryam M. Elmi[1], Fatemeh Elmi[2], Chiman Ghaderi[3], Farideh Feizi[4*]

1. Cellular and Molecular Biology Research Center (CMBRC), Health Research Institute, Babol University of Medical Sciences, Babol, Iran.

2. Department of Marine Chemistry, Faculty of Marine & oceanic sciences, University of Mazandaran, Babolsar, Iran.

3. Department of Radiation Technology, Paramedical Faculty, Babol University of Medical Sciences, Babol, Iran.

4. Department of Anatomical Science, and Cellular and Molecular Biology Research Center (CMBRC), Health Research Institute, Babol University of Medical Science, Babol, Iran.

Submitted 3 Jul 2022; Accepted 27 Jan 2023; Published 29 Feb 2024

Treatment of diabetic ulcers is associated with a failure in wound healing. While collagen dressing was applied effectively in wound healing, today, advanced dressing designs that can accelerate healing has received attention. Tissue homogenates glycolipoprotein (G-90) contains some growth factors that can participate in healing. The present study examined the wound healing effects of fish scale collagen sponge along with G-90 on sutured incisions in diabetic rats. G-90 was isolated from earthworm (*Eisenia foetida*). Type 1 collagen was purified from fish scales and lyophilized in sponge form. The sponges were immersed in 10 ng of G- 90. The efficacy of collagen sponge/G-90 was evaluated on sutured incisions in STZ-induced diabetic rats on days 4, 8, 14, and 18 through a morphological and histological approach. The results demonstrated that collagen sponge/G-90 is effective as a wound healing accelerator all days after wounding. Re-epithelialization and angiogenesis were significantly better in the treated group with collagen sponge/G-90 ($P \leq 0.05$). Experimental data demonstrated that collagen sponge/G-90 increased fibroblast proliferation, vascularization, collagen synthesis, and collagen fibril diameters. Considering the existence of many growth factors in G-90 and the role of collagen in the extracellular matrix, we conclude that the collagen sponge/G-90 could be a natural mixture for the management of wound healing. Additional studies are proposed to approve it as a wound-healing agent.

Keywords; collagen sponge; G-90; diabetic rat; earthworm; wound healing

Diabetes mellitus is a common chronic metabolic disease, with high prevalence (1). Previous studies predicted that the prevalence of diabetes is increased to about 2 million in 2030(2). Chronic foot ulcers affect the quality of life and lead to *amputation of approximately 15 to 20 %* in diabetic patients. The wound healing contains cellular and molecular events that several growth factors are involved in regulating these steps(3)(4)(5). In diabetic patients, the wound healing process is performed with delay and often gets stuck in the inflammation step(6). Recent research has developed our understanding of wound healing(7). Many studies were performed to find new materials to accelerate the process ofwound healing (8)(9)(10).

*Correspondence: Department of Anatomical Science, Babol University of Medical Science, Babol, Iran. E-mail: feizi.dr@gmail.com

[Downloaded from ibbj.org on 2026-11-25]

G-90 obtained from the tissue earthworms possess many biological activities that exert anti-coagulative, bacteriostatic, mitogenic, anti-oxidative, fibrinolytic, and agglutinative activities(11). Previous studies indicated that G-90 extracts participates in the wound-healing process by influence tissue regeneration, wound closure, the formation of the extracellular matrix, granulation**,** enhanced re-epithelialization(11). Our previous study on wound healing in a diabetic rat also demonstrated that G-90 improved extracellular matrix formation, increased collagen synthesis, and induced fibroblast proliferation(12).

Collagen has very important role in wound healing. They distribute in soft and hard connective tissues and type I collagen includes about 70% of the collagen in the skin(13). In the wound healing, the type III collagen is first made, then gradually it is replaced by type I collagen which increases the tensile strength of the wound (14). Intrinsic biocompatibility and biodegradability make exogenous collagen ideal for use in biomedical applications. Collagen, mostly type I, acts as a scaffold in connective tissue. Type I collagen is utilized to wound healing and can affect tissue granulation, wound contraction, and re-epithelialization (15). Additionally, collagen has revealed low antigenicity, stimulate fibroblast production, motivate wound healing, and delivery of bioactive agents (such as growth factors)(16)(17)(18). With this special efficacy, it can be considered as an ideal biomaterial for wound dressing applications and tissue engineering(19).

A foot ulcer is the most frequent chronic complication in diabetic patients. Treatment of diabetic ulcers is prolonged, expensive, and sometimes not effective(6). The poor response of diabetic patients to existing therapeutic products has led researchers to look for more effective drugs. Today the use of combination drugs in wound healing has attracted enormous interest(20)(21)(22). As mention above, several studies have shown the impact of the G-90 and also collagen dressing on wound healing. The most aim of this study was to enhance wound healing. In this study collagen extracted from white fish scales (a waste from fishery) and G-90 extracted from the homogenate of *Eisenia foetida*. Then, collagen sponge along with G-90 prepared and used to survey wound healing.

Materials and Methods

The Caspian white fish (Rutilus Firisikutum) scales were collected from the fishery and transferred to the laboratory on ice. Earthworms, *Eisenia foetida* (Annelida, Oligochaeta, Lumbricidae), were taken care of in humid cow compost at 20°C in darkness for 14days. The bioactive mixture G-90 was extracted from extraction tissue homogenate.

Collagen isolation and G-90 extraction

Collagen was purified and characterized from fish scales as it was described later (23). Briefly, the washed fish scales were soaked in 20 mM EDTA, 1 M NaCl, and 50 mM Tris- HCl solution at pH = 7.5 for 48 h. After that, collagen was isolated from demineralized fish scales with 0.5 M acetic acid for 3 days at 4 °C and centrifuged at 3000 g for 15 min. The supernatants were salting-out by adding NaCl 0.9 M at 4 °C. After centrifuging at 8000 g for 1 h, the pellet was solubilized in 0.5 M acetic acid and dialyzed through a dialysis membrane (cut-off range 3 kDa) toward 0.1 M acetic acid.

Earthworms G-90 extraction was started by adding a 0.65% NaCl solution. After spotless the digestive system, their body was cut into small pieces and homogenized within the equal part chloroform-methanol solution (v/v) at 4°C overnight. Next, distilled water was added, and it was centrifuged at 2460 g for 10min. The methanol was evaporated from the water/methanol solution(13).

Type 1 Collagen was lyophilized in sponge form and the sponges were cut in 2 x 2 cm. Then, they were immersed in a G-90 solution (10 ng/ml) and gently squeeze out excess. The product was sterilized by ultraviolet light.

Galley Proof

[Downloaded from ibbj.org on 2026-11-25]

Skin samples

Forty adult albino Wistar female rats weighing 200–250 g were selected from the Animal House of Babol University of Medical Sciences. The animals were kept in steady-state in a clean cage under controlled conditions (25 ± 2°c, humidity 50%). The animals were fed with standard laboratory food and were exposed to 12 h light-darkness cycles.

Induction of diabetes in overnight fasted rats was carried out using 50 mg/kg of STZ dissolved in sodium citrate solution (0.01 M, pH 4.5) which was prepared immediately before injection. The rats were fed with an ordinary diet and 10% sucrose. The rats with the blood glucose level of more than 250 mg/dl were suggested for the next study. After that, they were established for anesthesia by intraperitoneal injection of Ketamine- Xylazine (2:1). The nap region skin became bald and circular wounds (2 cm in diameter) were generated. Rats were divided into 5 groups (n = 8) each in a separate clean cage and treated for 18 days on site of the wound. Group (A) diabetic rats that were left without any treatment as a negative control, and group (B) diabetic rats were cured with G-90 (10 ng/ml). Collagen sponge was used for group C and group (D) were treated with collagen sponge/G-90. The positive control was a group (E) that was cured by using D-Panthenol. On days 0, 4, 8, 14 and 18 the diameter of wounds was measured through the photometric method with a digital camera (Nikon Coolpix S 6300, Tokyo, Japan). They were killed on days 4, 8, 14, and 18 by ether inhalation. The entire skin encircling healing wounds was removed and placed in formalin 10% (v/v).

Wound contraction rate

The wound surface area was analyzed on days 0, 4, 8, 14 and 18 by the photometric method (Motic images plus 2) in square micrometers. The wound contraction rate was calculated through the following equation:

$$Wound \text{ contraction rate} = \frac{A0-Ad}{A0} \times 100$$

A0 is the wound area on days 0 and Ad is the wound area on days after treatment.

Histological Analyses

Wound samples were embedded into the paraffin and cut into 5 µm thickness. Tissue sections were stained with hematoxylin/ Eosin or Trichrome. Next, they were examined by an Olympus BX41 microscope. Tissue granulation, connective tissue, collagen tissue, and fibroblast formation, and re-epithelialization were investigated.

Statistical analyses

Statistical analyses were carried out through IBM SPSS Statistics 24. The post hoc test (Tukey's method) for one-way analysis of variance (ANOVA) was used for comparing data. 'p values'<0.05 were considered significant.

Results

General characteristic of animals

The mean ± SD of rats' weight was illustrated in Table 1. A slight difference in the weight of rats was observed before and after treatment.

Wound Contraction Rate

We observed that the best wound healing process was obtained in the animals treated with collagen sponge/G-90. The wound contraction rate (WCR) was evaluated by the percentage of wound area at a different time compared to that of the 0 days. Figure 1 shows the progression of wound contraction at given times in diabetic rats. The wound contraction was remarkable in the treated group compared to the control. As illustrated in Figure. 2, the process of wound contraction among the treated groups B, C, and D was similar. The percentage of wound contraction among the treated groups was similar on the 18th day, (in groups B (97.58%), C (96.59%), D (99.06%), and E (96.78%). However, it was 57.03 % in diabetic rats without treatment. Statistical analysis demonstrated significantly higher wound contraction rates from the treated groups compared that from the control (A) all over the morphometric assessment time (4 to

Galley Proof

[Downloaded from ibbj.org on 2026-11-25]

Table 1. The average weight of rats is shown on the first day and the day before slaughter. Group (A) diabetic rats were left without any treatment, group (B) diabetic rats were cured with G-90 (10 ng/ml), group C were treated with Collagen sponge, and group (D) were treated with collagen sponge + G-90, and group (E) were treated with D-Panthenol

Time	Average of Weight				
	Group A	Group B	Group C	Group D	Group E
Before Treatment	185.43 ± 6.42	189.65 ± 5.50	180.43 ± 7.35	183.57 ± 7.19	192.12 ± 3.26
After Treatment	183.22 ± 7.23	189.29 ± 2.87	184.25 ± 8.1	185.60 ± 5.34	189.43± 4.71

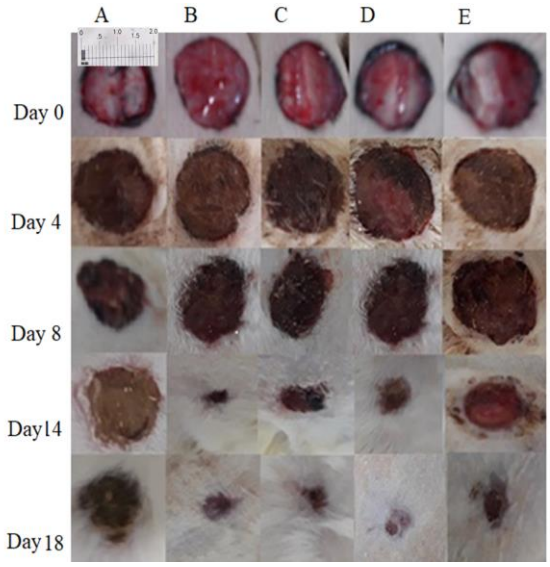

Figure 1. Photographs of excision wounds of rats from group (A) diabetic rats were left without any treatment, group (B) diabetic rats were cured with G-90 (10 ng/ml), group (C) were treated with Collagen sponge, group (D) were treated with collagen sponge + G-90, and group (E) were treated with D-Panthenol. In group treated with collagen sponge + G-90, wound contraction was noticeable.

18), while a difference was not significant between the treated groups.

Histological Study

The tissue sections obtained from all groups were used for histological studying on 4, 8, 14, and 18- day post- wounding. The tissue sections were stained by Hematoxylin/eosin or Trichrome. All groups are similar in terms of appearance on the fourth- day post- wounding. Despite the apparent similarity, the histological examination displayed that the tissue sections in the B, C, D and E group show that the epidermis is formed with scab at the wound edges. Initial granulation tissue, newly formed blood vessels, many inflammatory cells (mainly neutrophils and macrophages) are detected in the bed of wounds. Also, Keratinocytes transfer under the scab from the thickened edges of the epidermis to the middle of the wound. In the deep parts, abundant fat cells and some collagen strands

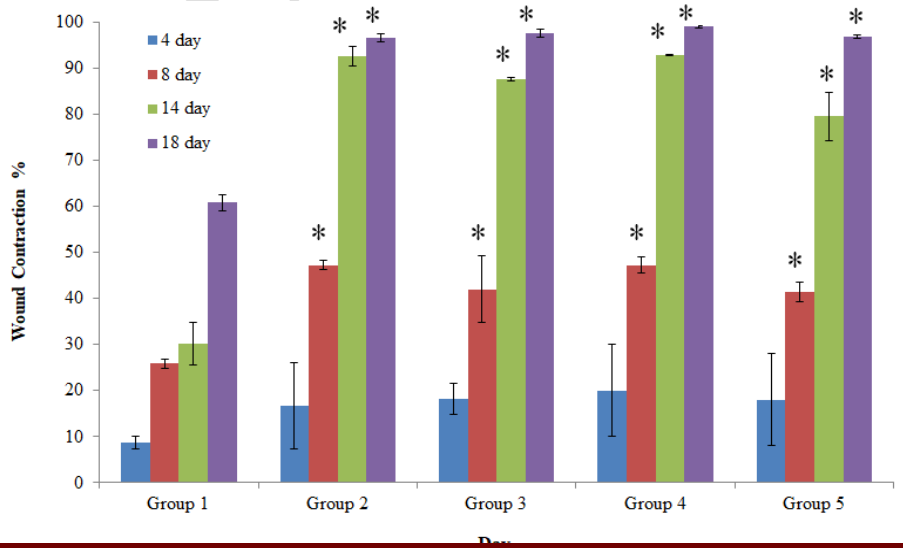

Figure 2. Wound contraction percent from group (A) diabetic rats were left without any treatment, group (B) diabetic rats were cured with G-90 (10 ng/ml), group (C) were treated with Collagen sponge, group (D) were treated with collagen sponge + G-90, and group (E) were treated with D-Panthenol. Means ± SD Values were obtained from 3 independent experiments. P* < 0.05 vs. group (A) diabetic rats.

[Downloaded from ibbj.org on 2026-11-25]

are formed in both groups treated by G-90, while the surface is still granulated. However, in group A, scab was found at the wound surface, and below it, fibrinoid tissue, and blood vessels. In the deeper parts of the wound, cell density was very low, in some cases, fibroblasts were found, and inflammatory cells were seen even in the muscular part. Also, a large number of polymorphonuclear cells and macrophages were observed. The edges of the wound are formed by some epidermis with a rudimentary surface layer.

On 8- day post-wounding, in groups B and D, at the edges of the wound, the epidermis is formed. On the surface, fat tissue, and inflammatory cells are not much. A small amount of fat is seen in depth. In deeper parts, the thick collagen strands were also formed. In group A, the sections show that the epidermis was thick and it was regionally formed. Connective tissue was granulated. The number of polymorphonuclear leukocytes displayed noticeable. In the other groups, a noticeable reduction is observed in the number of polymorphonuclear cells. Also, unorganized collagen was also formed.

On 14- day post- wounding, in all treated groups, a thick epidermis was observed on the edges of the wound, adipose tissue cells were much less visible, and granular tissue is still seen. In addition, epithelialization and fibroplasia were more frequent in the treated groups than in the control group. Also, inflammatory cells and newly created blood vessels presented a significant decrease in treatment groups. In the deep parts, abundant fibroblasts are observed. In addition, in group D, treated with collagen sponge/G90, the thick and mature collagen strands are notable (Figure. 3b). In group A, a wide area of the wound was still open. The edges of the wound were thick with the irregular epidermis, and underneath, it was still immature. Blood capillaries were very large at the wound's surface. The tissue was granular. Collagen fibers were seen as thin and immature (Figure 3b).

On 18- day post- wounding, in all treated groups, all layers of the epidermis were well developed and stratum basalis, spinosum, granulosum were formed. The sides of tissue have perfectly normal skin with hair follicles and sebaceous glands. In group D, the dermis is quite collagenous and mature. In the deeper parts of the wound, macrophages, inflammatory cells, and single-core myoblast were observed. In group E (D-Panthenol), in the middle of the wound, skin appendages were low. There are plenty of elastic strings, but collagen strands are very delicate. The epidermis was formed, but in the dermis, collagen fibers were not completely mature. In deep areas, large capillaries were seen, but inflammatory cells were not seen.

In group A, the wound surface was still open and was covered by a scab. At the edges of the wound, there was a large epidermis. Also, collagen strings have not matured yet. Furthermore, inflammatory cells were seen that explained the failure of the wound healing process.

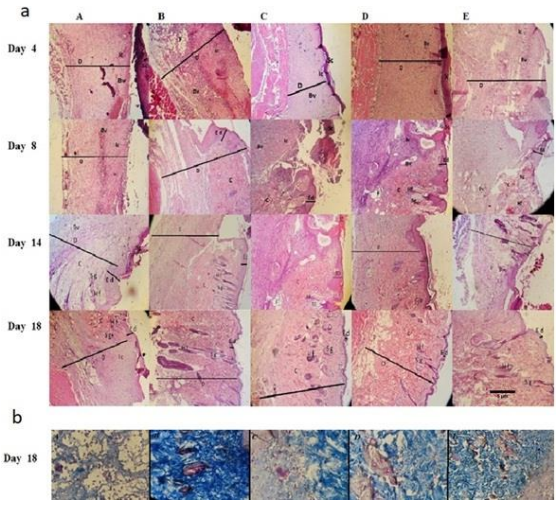

Figure 3. Skin wound section stained on 4-, 8-, 14-, 18-day post wounding, a) H & E and b) trichrome (×10). Group (A) diabetic rats were left without any treatment, group (B) diabetic rats were cured with G-90 (10 ng/ml), group (C) were treated with Collagen sponge, group (D) were treated with collagen sponge + G-90, and group (E) were treated with D-Panthenol. Treatment on rats revealed (Ep) Epidermis, (Sb) scab, (D) dermis, (Bv) blood vessel, (C) collagen fibril, (HF) hair follicle, (Sg) sebaceous gland. Collagen fibril was stained blue in trichrome staining.

Galley Proof

[Downloaded from ibbj.org on 2026-11-25]

Discussion

Experimental data indicate that chronic wounds, especially diabetic ulcers do not follow an orderly reliable progression of healing. In this process, several synchronized events promote healing; inflammation, proliferation, and maturation. Unfortunately, diabetic foot ulcers often stroke in inflammatory(24). Collagen products, as a scaffold in connective tissue, have the ability to combine with growth factors, cytokines, and antimicrobials to accelerate granule tissue, re-epithelialization and wound contraction. G-90 is a glycolipoprotein complex that takes parts on the wound-healing process by influence tissue regeneration, wound closure, and the formation of the extracellular matrix. In this study, we used collagen sponge along with G-90 for accelerating wound healing in diabetic rats. The results demonstrated that collagen sponge/G-90 is effective as a wound healing accelerator in diabetic rats all days after post wounding. Morphometric results showed that the wounds from the treated with collagen sponge/G-90 have higher contraction rates than other groups throughout the entire assessment days. The first stage in wound healing is homeostasis, which is associated with contracting blood vessels and reducing bleeding during the vasoconstriction process. G-90 have blood clotting activity, fibrinolysis and anticoagulation properties. Also, G-90 contains epithelial growth factors (EGF) that can be reflected in the key regulators of keratinocyte proliferation and fibroblast growth factors (FGF),(12)(25). Fibroblasts and keratinocytes, by producing many cytokines and growth factors, stimulate the proliferation and differentiation of cells in the wound bed (26). The results of this finding are consistent with the results of previous studies. In a study, the wound healing process on rats demonstrated that the percentage of wound closure in rats receiving topical G-90 extract daily was 71% and the group receiving panthenol ointment was 61%. The rate of re-epithelization in the group receiving G-90 was 1.2- 1.75 times faster than other groups(12).

Also, previous studies indicated that collagen have a hemostatic and thermostatic function, and support the vasoconstriction process (27). Moreover, collagen plays an important role in the growth of new capillaries and increased fibroblastic activity, which leads to a reduction in contraction in a wound (27). In this stage, cytokines and growth factors such as platelet-derived growth factor (PDGF), FGF, and EGF released in the wound area and following that macrophage cells immigrate into the wound(28)(4). Our histological data show that extensive macrophages are seen in the treated group with collagen sponge/G-90 in 4 days after wounding. The previous study indicated that macrophages are important for activating keratinocytes, fibroblasts and endothelial cells (28). The macrophage-derived cytokines are involved in angiogenesis, fibroblast migration and proliferation, collagen production and possibly wound contraction(3)(28). Mitogen activity and FGF activity of G-90 could be handling the proliferation of fibroblasts(12). Fibroblasts play an important role in wound healing treatment. They involve in the synthesis of small amounts of extracellular matrix and collagen, especially in the deeper wound areas. In the current study, the histological analysis from different groups on the 4th day after wounding showed many inflammatory cells, such as neutrophils and macrophages in group D (collagen sponge/G-90). In group E, many polymorphonuclear cells are also found in the deep part but less than group D. On the 8th day after the wound, the inflammatory cells are significantly reduced in the treated groups that may be recognized to the capacity of anti-inflammatory and antioxidant activities of G-90 (29) and collagen(17)(21). The prevalence and frequency of polymorphonuclear cells are seen in group A even in the next stages of healing, proposes an elongated inflammatory process. It has been recognized that prolonged inflammation is associated with edema and loss of function, resulting in a failure in wound healing

Galley Proof

[Downloaded from ibbj.org on 2026-11-25]

(24).

In other words, it can be claimed that the effect of collagen/G-90 on the progression of diabetic wound healing in the treatment group was initially triggered by a quicker inflammation and was terminated more quickly. Therefore, they may be effective in increasing the transition of the inflammatory phase, entering the phase of fibroplasia and ultimately increasing the wound healing process. Also, exogenous application of collagen at the site of the wound helps to the fibroblast production and support to keep macrophages, leukocytes, fibroblasts(30)(18). On the other hand, the fibroblasts synthesized collagens (28) that protected the healing process via the healthy collagen from a matrix metalloproteinases break down(18).

An important part of wound healing is due to angiogenesis. Our study was also showed higher neovascularization in the treated group with collagen sponge/G-90 in 4 days after wounding. Angiogenesis improves oxygen supply and nutrients for wound healing(30).

In 8 days after wounding, granular connective tissue supports cell migration, stimulates and moves fibroblasts faster to the wound site and stimulates the synthesis of collagen. At the stage of granulation and the beginning of the epithelial tissue formation, it continuously contributes to the supply of collagen needed to regenerate the wound and supports the formation of new fibers of collagen. It was explained that collagen scaffolds have a high level of adhesion to the cell and can support the vascularization process.

Considering the role of fibroblasts, which synthesize some components of the extracellular matrix such as fibronectin and proteoglycans, they provide a suitable substrate for cell migration and proliferation.

Regarding the importance of hair growth after repair of lesions resulting from the experimental wound, histological findings of this study were observed in treated groups with collagen sponge/G-90, the formation of hair follicles was more than others.

The last step of wound healing is controlled by improvement of the new epithelium and the structure of the scar tissue, which is important in the repair process (27). Replacing the old matrix with the new matrix is initially performed quickly and then more smoothly. When this primary matrix is replaced by more regular, stronger, and more durable fibers, wound fracture is lost. In the treated group (collagen sponge/G-90), collagen renewal is faster than in other groups, thicker collagen bundles are formed, and collagen bands are arranged regularly. It seems that G-90 along with collagen not only increases the amount of collagen in the wound but also modifies collagen structure, increasing cross-linking between these strands and thus accelerates wound healing.

Overall, the morphometric data and histological findings reveal that wound in diabetic rats treated with collagen sponge/G-90 was healed better and faster when compared to untreated diabetic rats. The presence of a type I collagen in the compound of G-90 facilitates the deposition of large-diameter the collagen fibers in the lower dermis.

Conclusion

The potential advantages of using collagen along with G-90 dressings can deliver a wide range of benefits to the wound healing process. They improve the healing rate, helps to stimulate the growth factors in the wound bed. The results indicated that collagen sponge/G-90 had outstanding wound healing effects on sutured incisions leading to rapid wound closure, anti-inflammatory properties, fibroblast proliferation, angiogenesis, and re-epithelialization.

Acknowledgements

We thank to all the participants for their kind collaboration. This work was supported by a grant (no. 9604212) from the research council of the Babol University of Medical Sciences. We also

Galley Proof

[Downloaded from ibbj.org on 2026-11-25]

thank the Cellular and Molecular Biology Research Center, Health Research for supporting this research.

Conflict of interest

The authors declared no conflict of interest.

References

1. Hameed I, Masoodi SR, Mir SA, Nabi M, Ghazanfar K, Ganai BA. Type 2 diabetes mellitus : From a metabolic disorder to an inflammatory condition. World J Diabetes 2015. 2015;6(4):598–612.

2. Shaw JE, Sicree RA, Zimmet PZ. Global estimates of the prevalence of diabetes for 2010 and 2030. Diabetes Res Clin Pract. 2010;87:4–14.

3. Martin P.and Nunan R. Cellular and molecular mechanisms of repair in acute and chronic wound healing. British Journal of Dermatology. 2015; 173: 370- 378.

4. Guo S, Dipietro LA. Factors Affecting Wound Healing. Crit Revievs Oral Biol Med. 2010;89(3):219–29.

5. Su L, Zheng J, Wang Y, Zhang W, Hu D. Biomedicine & Pharmacotherapy Emerging progress on the mechanism and technology in wound repair. Biomed Pharmacother [Internet]. 2019;117:109191. Available from: https://doi.org/10.1016/j.biopha.2019.109191.

6. Karen Ousey, Arkadiusz Jawień, Gulnaz Tariq, Harikrishna K Ragavan Nair, José Luis Lázaro-Martínez, Kylie Sandy-Hodgetts, Paulo Alves, Stephanie Wu WMZM. Identifying and treating foot ulcers in patients with diabetes : saving feet , legs and lives. J Wound Care. 2018;27(5):1–52.

7. Ning Xu Landén, Dongqing Li and MS. Transition from inflammation to proliferation: a critical step during wound healing. Mol Life Sci. 2016;73(20):3861–85.

8. Colobatiu L, Gavan A, Potarniche A, Rus V, Diaconeasa Z, Mocan A, et al. Evaluation of bioactive compounds-loaded chitosan fi lms as a novel and potential diabetic wound dressing material. React Funct Polym [Internet]. 2019;145:104369. Available from: https://doi.org/10.1016/j.reactfunctpolym.2019.104369.

9. Rao SS, Venkatesan J, Prabhu A, Rekha PD. Natural polymeric biomaterials in growth factor delivery for treating diabetic foot ulcers. J Drug Deliv Sci Technol. 2019;101385.

10. Zintle Mbese, Sibusiso Alven and Blessing Atim Aderibigbe Collagen-Based Nanofibers for Skin Regeneration and Wound Dressing Applications. Polymers 2021, 13, 4368. https://doi.org/10.3390/polym13244368.

11. Matau M, Ka V, Mikecin M, Grdi M. Tissue extract from Eisenia foetida as a wound-healing agent. Eur Rev Med Pharmacol Sci. 2010;14:177–84.

12. Goodarzi G, Qujeq D, Elmi MM, Feizi F, Fathai S. The effect of the glycolipoprotein extract (G-90) from earthworm Eisenia foetida on the wound healing process in alloxan-induced diabetic rats. Cell Biochem Funct. 2016.

13. Mathew-Steiner, S.S., Roy, S., Sen, C.K. Collagen inWound Healing. Bioengineering 2021, 8, 63. https://doi.org/10.3390/bioengineering8050063.

14. Aravindan Rangaraj, Keith Harding DL. Role of collagen in wound management. Wounds. 2011;7(2).

15. Rao BAR, Reddy RGVR, Sudhir A, College SVSM, Nagar M. RESEARCH ARTICLE COLLAGEN SPONGE DRESSINGS IN DIABETIC FOOT ULCERS. Int J Curr Res. 2015;7(8):19587–91.

16. Erika Maria Tottoli, Rossella Dorati, Ida Genta, Enrica Chiesa, Silvia Pisani and Bice Conti. Skin Wound Healing Process and New Emerging Technologies for SkinWound Care and Regeneration. Pharmaceutics. 2020, 12, 735; doi: 10.3390/pharmaceutics12080735.

17. Li B, Chen J, Wang JH. Promotes Adhesion , Proliferation , and Collagen Secretion of Human Fibroblasts. J Biomed Mater Res A. 2006;79(4):989–98.

18. Chattopadhyay S, Raines RT. Collagen-Based Biomaterials for Wound Healing. Biopolymers. 2014;1–42.

19. Holmes C, Wrobel JS, Maceachern MP, Boles BR. Collagen-based wound dressings for the treatment of diabetes-related foot ulcers : a systematic review. Diabetes, Metab Syndr Obes Targets Ther. 2013;6:17–29.

20. Ruth Naomi, Hasnah Bahari, Pauzi Muhd Ridzuan and Fezah Othman. Natural-Based Biomaterial for Skin Wound Healing (Gelatin vs. Collagen): Expert Review. Polymers. 2021, 13, 2319. https://doi.org/10.3390/polym13142319.

21. Erika Maria Tottoli, Rossella Dorati, Ida Genta, Enrica Chiesa, Silvia Pisani and Bice Conti. Skin Wound Healing Process and New Emerging Technologies for SkinWound Care and Regeneration. Pharmaceutics. 2020, 12, 735; doi: 10.3390/pharmaceutics12080735.

Galley Proof

[Downloaded from ibbj.org on 2026-11-25]

22. Mm WZ, Wang QFX, Mm XW, Zhang T, Shi MMB, Bin MM, et al. Chitosan-calcium alginate dressing promotes wound healing: A preliminary study. Wound Rep Reg. 2019;1–12.

23. Elmi F, Elmi MM, Amiri FN. Thermodynamic Parameters and Influence of Kinetic Factors on the Self-Assembly of Acid-Soluble Collagen Nanofibrils. Food Biophys. 2017;12(3):365–73.

24. Frank M. Davis, Andrew Kimball, Anna Boniakowski, Katherine Gallagher. Dysfunctional Wound Healing in Diabetic Foot Ulcers: New Crossroads. Current Diabetes Reports. 2018; 18:2. https://doi.org/10.1007/s11892-018-0970-z

25. Deng Z, Yin J, Luo W, Kotian RN, Gao S, Yi Z, et al. The effect of earthworm extract on promoting skin wound healing. Biosci Reports. 2018;38:1–11.

26. Jin Woo Park, Seung Rim Hwang and In-Soo Yoon. Advanced Growth Factor Delivery Systems in Wound Management and Skin Regeneration. Molecules. 2017; 22: 1259. Doi: 10.3390/molecules22081259.

27. Frank Pallaske, Anett Pallaske, Kurt Herklotz, Joachim Boese-Landgraf, The significance of collagen dressings in wound management: a review. Journal OF Wound Care. 2018; 27 (10):692- 701.

28. Yumiko Oishi1 and Ichiro Manabe. Macrophages in inflammation, repair and regeneration. International Immunology. 2018; 30 (11): 511– 528. doi:10.1093/intimm/dxy054.

29. Grdisa M, Popovic M, Hrzenjak T. Glycolipoprotein extract G-90 / from earthworm Eisenia foetida exerts some antioxidative activity. Comp Biochem Physiol Part A 128. 2001;28:821–5.

30. Johnson KE, Wilgus TA. Vascular. Endothelial Growth Factor and Angiogenesis in the Regulation of Cutaneous Wound Repair. Wound Heal Soc. 2014;3(10):647–61.

Galley Proof

[Downloaded from ibbj.org on 2026-11-25]