

Spatial Memory, Motor Coordination, Cerebellar and Hippocampal Histoarchitectural Changes following Atropine Administration to Adult Mice

Linus Anderson Enye¹, Edem Ekpenyong Edem^{1,2*}, Azeez Olakunle Ishola¹, Mary Essien Umoh¹, Nneoma Achonwa-Njemanze¹, Abimbola John Ajay²

1. Department of Anatomy, College of Medicine and Health Sciences, Afe Babalola University, Ado Ekiti, Nigeria.

2. Department of Anatomy, College of Medicine of the University of Lagos, Lagos, Nigeria.

Submitted 8 Apr 2017; Accepted 5 May 2017; Published 13 Jun 2017

Atropine is a non-selective muscarinic receptor antagonist. In overdoses, atropine is poisonous. It is sometimes added to potentially addictive drugs, particularly anti-diarrhoea opioid drugs such as diphenoxylate or difenoxin. The aim of this study was to investigate spatial memory and motor changes associated with varying doses (5 and 10 mg/kg body weight) ingestion of atropine, as well as its impact on the hippocampal and cerebellar histoarchitecture in mice. Fifteen BALB/c mice were divided into three groups of 5 serving as control, low dosage, and high dosage groups. Atropine at 5 and 10 mg/kg body weight was administered into low and high dosage groups, respectively. Administration of atropine in both groups showed significant histological tissue damage in the hippocampus which includes neurodegeneration of neurons and distortion of the granular layer, while no evident histomorphological change to the cerebellum was observed. Low dosage mice showed memory and motor deficit, whereas the high dosage group showed no statistically significant memory function difference with the control group. Further research is necessary to find the cause of these motor deficits.

Keywords: Atropine, spatial memory, motor coordination, cholinergic system, hippocampus, cerebellum

Atropine is an anticholinergic drug known to inhibit the enzyme, acetylcholinesterase (1). It is deleterious when abused recreationally. The delirium produced is characterized by confusion and depressive behaviors (2). However, in clinical doses it is safe for the central nervous system, although it has been shown to stimulate the medulla oblongata and the brain's higher centers (3). Atropine is a naturally occurring chemical which is the major active component in plants such as the deadly nightshade, *Atropa belladonna* and the *Datura*. These plants, though medicinal, have equally been reported to possess varying degrees of systemic

toxicities including hyperthermia, tachycardia, bizarre behavior, and severe mydriasis with resultant extensive painful photophobia. In India, *Datura* leaves are smoked to relieve asthma with a mechanistic paralysis of the pulmonary branches of the lungs to remove the spasms that produce the asthmatic attacks (4, 5), and also as an antiviral treatment for rabies infection (6). "Hot as a hare, blind as a bat, dry as a bone, red as a beet, and mad as a hatter" is a common mnemonic to express the physiological features of atropine overdose (7). At the moment, there is a paucity of data on the mechanistic impacts of atropine on the memory and

*Correspondence: Department of Anatomy, College of Medicine and Health Sciences, Afe Babalola University, Ado Ekiti, Nigeria.
E-mail: edemekpenyongedem@gmail.com

motor systems. Atropine, though naturally occurring in plants has been commercially prepared and utilized for a variety of medical purposes. However, as atropine contains hallucinogenic properties, it has been abused as a recreational drug. Hence, this work seeks to unravel the memory and motor systems dangers associated with the abuse of this drug for recreational and/or 'non-therapeutic' purposes.

Materials and methods

Animals

Fifteen male healthy BALB/c mice weighing between 30-35 g were sourced from the animal house of the Afe Babalola University, Ado Ekiti. They were kept and housed under laboratory conditions of temperature, humidity and light. They were allowed to acclimatize for a period of two weeks and fed with growers mash. After two weeks, the mice were weighed and were randomly distributed into three groups: A as control group, B and C as the treatment groups. All procedures were done in accordance to the research ethics committee of the Afe Babalola University, Nigeria.

Source and administration of atropine

Atropine was sourced locally from Tolu-pakad Pharmacy, Ado-Ekiti, Ekiti State, and was administered intraperitoneally at 5 and 10 mg/kg body weight using an insulin syringe.

Behavioural studies

Spatial memory was assessed using Y-Maze test (8). Rotarod test was done to assess the motor function of the animals after atropine was administered to the experimental animals (8). Parallel bar test was also performed as a motor function evaluation assay (8).

Histological analyses

At the end of the experiment, the mice were sacrificed by cervical dislocation. The brain was collected and fixed in 10% formal saline. The brain tissue, was passed through a process of tissue processing. The routine stains used were haematoxylin and eosin (H & E); and cresyl fast violet staining was employed to demonstrate Nissl

body density.

Statistical analyzes

Statistical analyzes were done using analysis of variance (ANOVA) and LSD posthoc. Data was expressed as mean \pm standard deviation. A P value less than 0.05 was considered as statistically significant.

Results

Histologic changes in the granular cells of the hippocampus

The cornus ammonis rings and the three layers of the dentate gyrus are shown in Figures 1 A and B. The polymorphic and molecular layers are made up of few interneurons and nerves branching together which forms a neuropil. Next to the polymorphic layer is the granular layer. The granular layer is made up of predominantly abundant granular neurons with deeply basophilic nuclei centrally located (arrow head). Nuclear cytoplasmic nuclei are 3:4, and the cell membrane appears indistinct. Also, oligodendrocytes scattered within the tissue stroma were observed. These features are in accordance with normal mouse hippocampal dentate gyrus cytoarchitecture. Figures 1 C and D reveal numerous granular cells disposed within the granular layer of the dentate gyrus. The Nissl substances within the cytoplasm of the granular cells appeared deep purplish blue with some prominent basophilic nuclei centrally located and a prominent nucleolus. Oligodendrocytes were present with pericyto-plasmic hallow. These altogether point to a normal hippocampal histoarchitecture.

Histologic changes in the hippocampal layers of mice exposed to low dose of atropine

The dentate gyrus, cornus ammonis, and subiculum are shown in Figures 2 A and B. The cornus ammonis was made up of pyramidal neurons as its predominant cell layer. Within the granular cell layer, dense basophilic cytoplasm and chromatolyzed cells with non-prominent fragmented nuclei were present. Cell membrane appeared indistinct. Also, abundant oligodend-

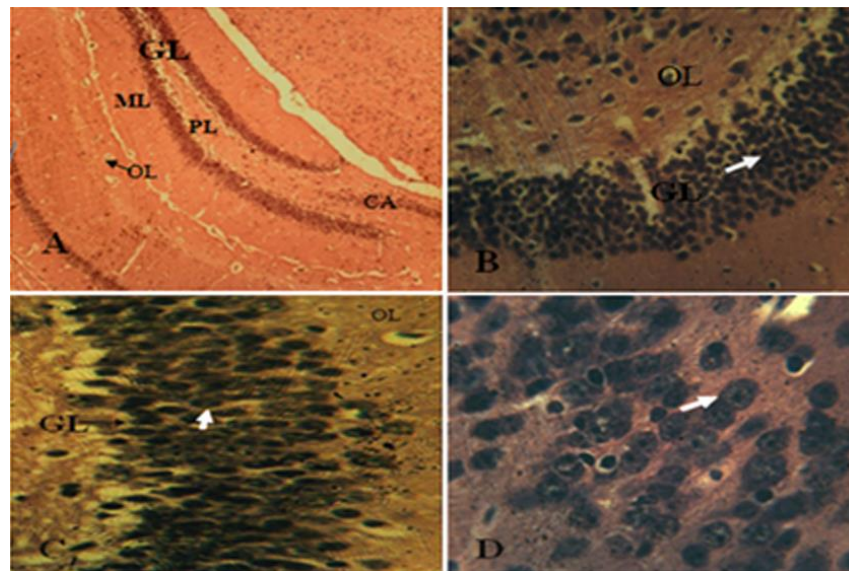


Figure 1. Photomicrographs of the hippocampus of control animals. A, B: H & E staining observed at x100 and x400 magnification, respectively; C, D: cresyl fast violet staining observed at x100 and x400 magnification, respectively. Both stains reveal a normal granular layer (GL), oligodendrocyte (OL), molecular layer (ML), polymorphic layer (PL) and cornus ammonis (CA) hippocampal histomorphology.

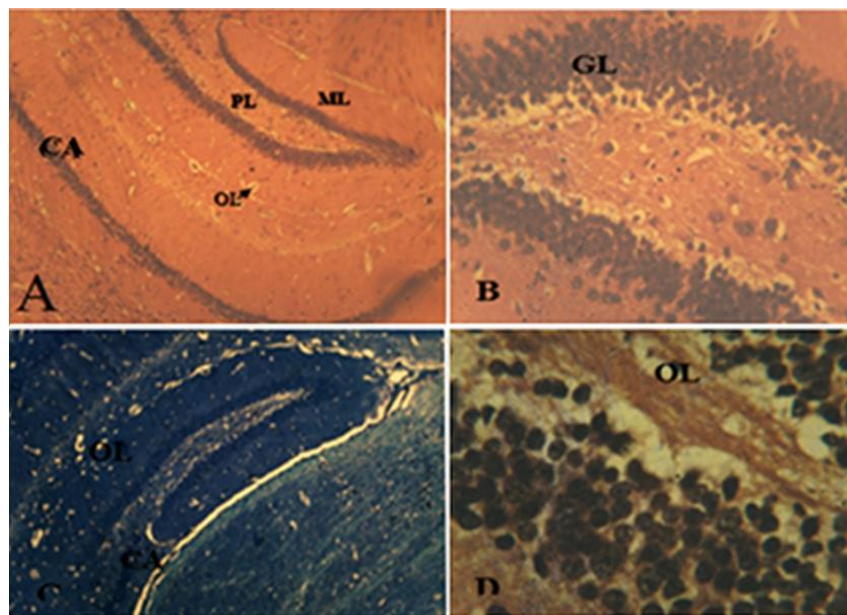


Figure 2. Photomicrographs of the hippocampus of animals with administration of low dose (5 mg/kg) atropine. A, B: H & E staining observed at x100 and x400 magnification, respectively; C, D: cresyl fast violet staining observed at x100 and x400 magnification, respectively. GL: granular layer; OL: oligodendrocyte; ML: molecular layer; PL: polymorphic layer; CA: cornus ammonis (CA).

rocytes with pericytoplasmic hallow were seen within the tissue stroma . These features are in keeping with loss of cellularity, hypoplasia and mild neurodegeneration of the dentate gyrus with Gliosis. Figures 2 C and D show pale stained granular neurons which were presented with shrunken nuclei and slight dense chromatin granules. Within the granular layer few pigmented neuronal actively

dividing cells were present. The Nissl substances within the cytoplasm were composed of light dense stained granular cells with irregularly shaped nucleus. Abundant oligodendrocytes whose cytoplasm showed a pericytoplasmic hallow were also seen. These features reveal mild neurodegeneration of the dentate gyrus and gliosis.

Histologic changes in the hippocampal layers of

mice administered with atropine at a high dose

The hippocampus showing the dentate gyrus, which is made up of three layers is shown in Figures 3 A and B. The polymorphic and molecular layers were made up of few interneurons and nerves branching together which forms a neuropil. Next to the polymorphic layers, the granular layer was present. The granular layer was made up of necrotic granular neurons with cytoplasm and nuclear hallow, nuclear fragmentations and pyknotic nuclei (arrows). Also, oligodendrocytes scattered within the tissue stroma were seen. These features are in keeping with normal mice hippocampal dentate gyrus cytoarchitecture. Figures 3 C and D show distorted and disoriented granular layer of the dentate gyrus. Within the distorted granular layers necrotic neurons with nuclear fragmentation, and pyknosis (arrow head) were present in clusters. Also, abundant oligodendrocytes were seen. These features are in keeping with severe dentate gyrus neurodegeneration and gliosis.

However, an intact cerebellar histomorphology after low and high doses atropine administration was observed (Figure 4).

Behavioural Studies

After performing Y-Maze test, the comparison of the alternation percentages of the high and low

dose groups with the control group, revealed no statistically significant difference (Figure 5).

Regarding rotarod test, atropine caused a decline in motor function, resulting in a reduction of equally affected the number of times the animals held on to the rotating bar and rotated, together with latency of fall (LOF). On the other hand, atropine the bar (termed, passive rotation). When compared to the control, both LOF and passive rotation were significantly lower ($P < 0.05$) in animals treated with atropine (Figures 6 and 7).

During parallel bar test, a significant increase or decrease in the latency of turn (LOT) scores was observed when the experimental animals were compared with the control animals, adjudging abnormal motor coordination. The 5 mg/kg group had a low LOT score, while the 10 mg/kg group recorded a slightly higher (than control's) LOT score. However, these differences were not statistically significant. The time taken by the animals to reach the edge of the parallel bar was higher in the group administered with 10 mg/kg, which was statistically significant when compared to the control animals that spent lesser time. It can thus be inferred here that 10 mg/kg of atropine in mice induced motor dysfunction (Figures 8 and 9).

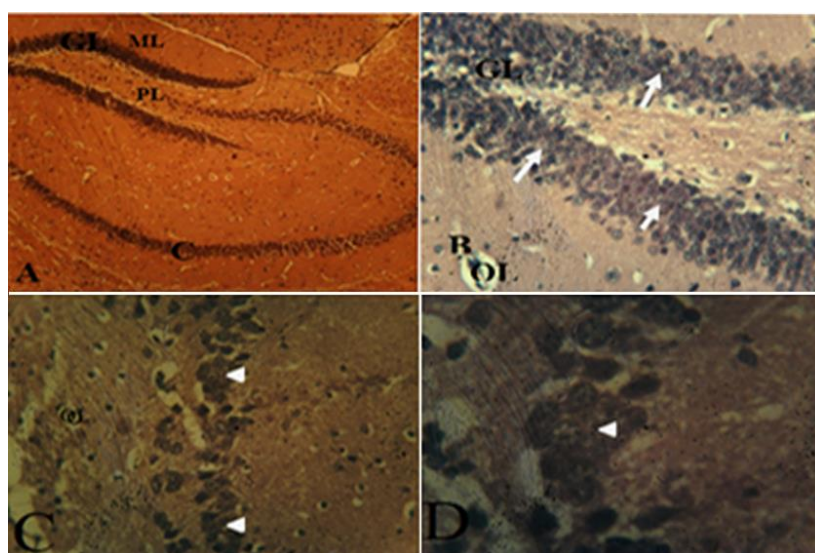


Figure 3. Photomicrographs of the hippocampus of animals with administration of high dose (10 mg/kg) atropine. A, B: H & E staining observed at x100 and x400 magnification, respectively; C, D: cresyl fast violet staining observed at x100 and x400 magnification, respectively. GL: granular layer; OL: oligodendrocyte; ML: molecular layer; PL: polymorphic layer; CA: cornus ammonis (CA).

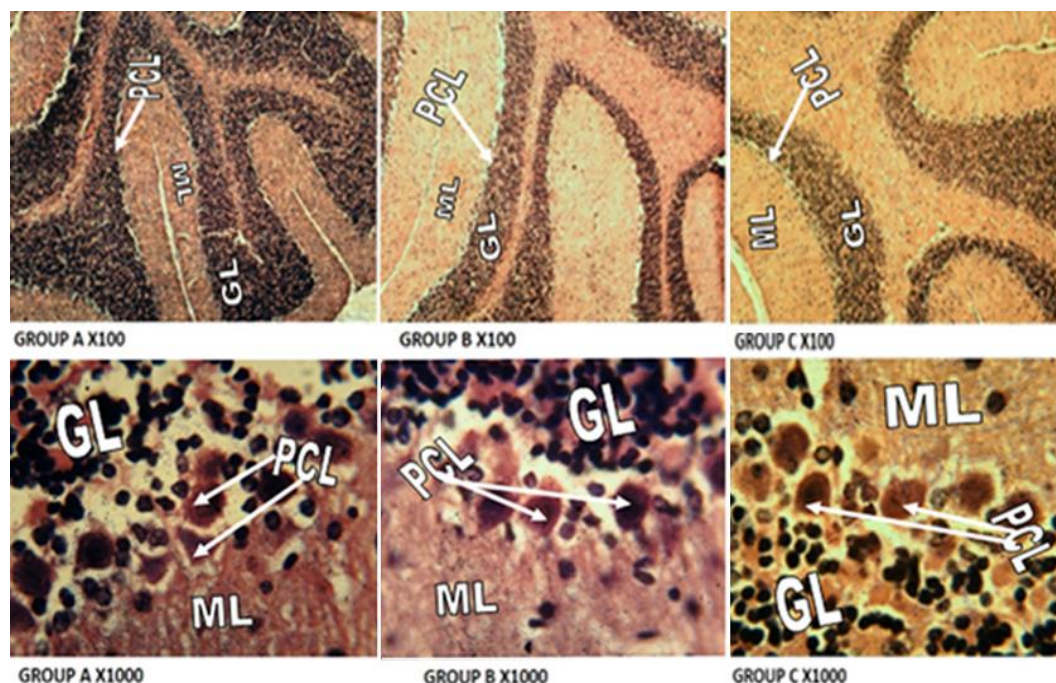


Figure 4. Photomicrographs of the cerebellar cortex. A: control group; B: low dose group; C: high dose group. The cerebellar cortex was stained with H & E method. The control group revealed normal cellular architecture of molecular layer (ML), Purkinje cell layer (PCL), granular layer (GL); groups B and C showed no significant histomorphological changes. The upper and lower panels correspond to x100 and x1000 magnification, respectively.

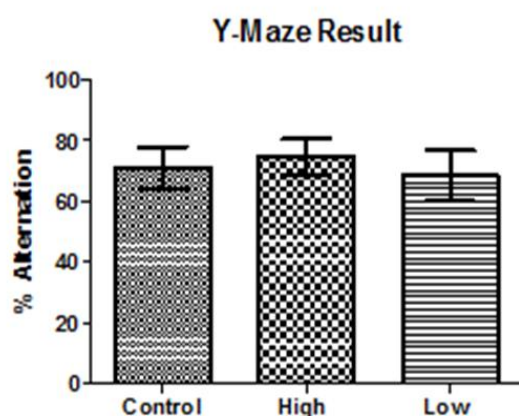


Figure 5. Percentage of experimental animals alternation. Animals with 10 mg/kg of atropine showed no significant difference with other groups.

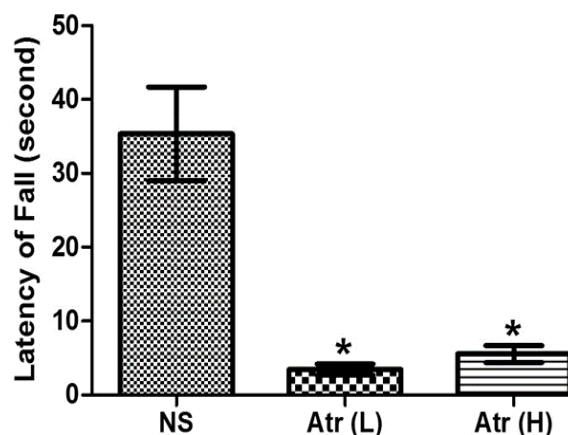


Figure 6. Rotarod test and latency of fall measurement. A significant difference (* $P < 0.05$) was obtained when the treatment groups Atr (L) (low dose) and Atr (H) (high dose) were compared with the control group (NS). The experimental groups spent lesser time on the Rotarod wheel thereby having a low latency of fall.

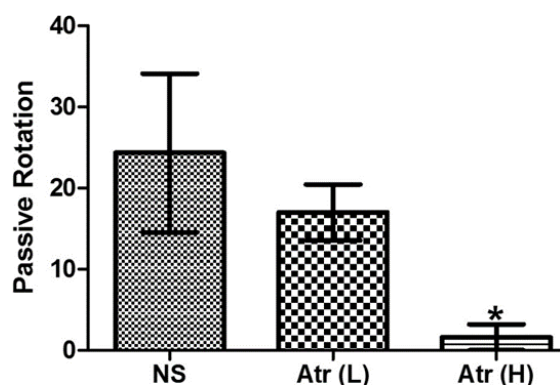


Figure 7. Passive rotation (PR) of the experimental animals on the Rotarod test. The number of times the animals held on to the rotating bar and rotate together with the bar is termed passive rotation. Passive rotation decreased in a dose-dependent manner during atropine exposure while the control (NS) animals had the highest value. Animals treated with high dose of atropine (10 mg/kg BW) had significantly lower PR compared to the control (* $P < 0.05$). Atr (L) and Atr (H) correspond to low and high dose of atropine, respectively.

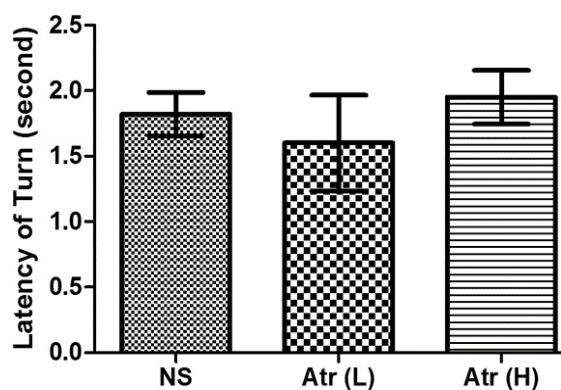


Figure 8. Latency of turn (LOT) of the experimental animals on parallel bar test. Animals treated with 5 mg/kg BW of atropine (Atr (L)) had the lowest LOT. ANOVA test showed no significant difference between groups ($P > 0.05$). NS: control; Atr (H): 10 mg/kg BW of atropine.

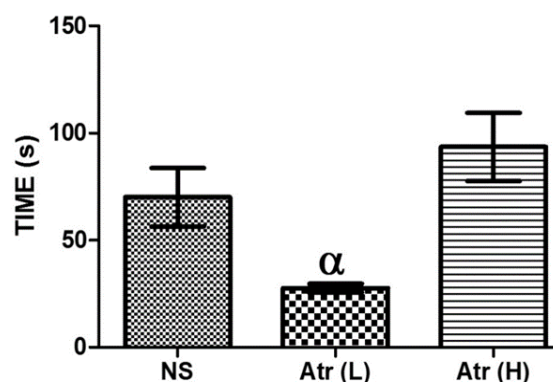


Figure 9. Evaluation of the time taken by the animals to reach the edge of the parallel bar. Animals given 10 mg/kg atropine BW (Atr (H)) spent more time before reaching the edge, followed by control (NS). Atr (L) (5 mg/kg atropine BW) animals had the lowest value which was significantly lower compared to Atr (H) ($P < 0.05$).

Discussion

The hippocampus plays a crucial role in memory, and damage to it and related systems is central to the amnesic syndrome (9). Atropine is a non-selective muscarinic receptor antagonist and when administered to the mice model in low doses, it binds to the muscarinic receptors in the hippocampus inactivating them, and causing a decrease in spatial memory. Studies by Ferreira et al. (10) and Benoit et al. (11) have shown that activating muscarinic receptors M1, M2 and M3 and the cholinergic system are implicated in improved memory consolidation. The study of Ferreira et al. showed that MT3, a selective antagonist for type M4 receptors caused amnesia and decrease in spatial memory (10). In similar circumstances, studies by Benoit et al. showed that M3 muscarinic receptor knockout mice, showed a deficit in fear conditioning learning and memory (11).

In the current study, in the low dosage group, due to the dosage administered, the atropine caused a blockage of the muscarinic receptors in the hippocampus, and was not able to elicit a marked impact on the cholinergic system causing a decrease in spatial memory. When administered in high dosage, however, this caused a marked impact on the cholinergic system and despite the blockage of the muscarinic receptors, the activation of the cholinergic system caused an insignificant increase

in the spatial memory index when compared to the control. However, studies by Picciotto et al. on the effect of high dosage of atropine administration in memory impaired mouse model showed that its activation of the cholinergic system counteracted its blockage of the muscarinic receptors causing no decrease in spatial memory (12).

The present study showed that both the low and high atropine dosage caused a decrease in the motor function when the treated mice groups were compared with the control. This was observed as a decrease in the latency of falls and latency of turns in both the rotarod and parallel bar tests, respectively. While the exact cause of these motor deficit is not known, two hypotheses could be drawn based on previous studies. It has been reported that the dentate nucleus of the cerebellum is responsible for delay in the initiation and termination of movement and that neurodegeneration of neurons in this region will lead to motor deficit (13). This is particularly so in multi-joint movements and in those requiring fine dexterity in the distal extremities. Consequently, the movement of an affected limb is delayed and slowed. The second hypothesis is that the dosage of atropine administered to the animals was high enough to elicit a blockade of nicotine receptors of the neuromuscular junction. This blockade will prevent the transmission of motor impulses to muscles and

will lead to motor deficit. More research however, is needed to verify both hypotheses.

High dosage of atropine administration showed distortion in the shape of neurons of the dentate gyrus of the hippocampus when compared with that of the control. The histological examination of the high dosage group showed neurons which were in some cases merged together, this is in sharp contrast to the neurons organization in the control group which were better spaced. Neurodegeneration was identified in the histological sections of the dentate gyrus region of the hippocampus of both low and high dosage atropine groups when compared with the control. These sections present shrunken nucleus and nuclear fragmentation in the granular layer of the dentate gyrus, abundance of glial cells with pericytoplasmic halo (mostly in low dosage), pigmentation of some neurons (mostly in low dosage) and pyknosis which was observed in high dosage group. This distortion is suspected to be caused by the functional disruption of acetylcholine activation by atropine and this agrees with the work of Picciotto et al. (12).

Degeneration of neurons in the cerebellum, cellular distortion, and loss of cells in the Purkinje cell layer degeneration are histopathologic signs of cerebellar disorders (14). In our study however, atropine administration both in high and low dosage showed no signs of histologic abnormalities compared with the control. This shows that atropine administration for seven-day duration brings about no changes in the histoarchitecture of the cerebellum.

Conclusively, this research attests that both high and low dosage of atropine administration produce motor function deficits; however, high dose administration has no statistically significant impact on memory function, although at low dosage there is memory deficit in the mouse model. It also reports the histomorphological alterations on the hippocampus which includes neurodegeneration of neurons and distortion of the granular layer. However, no remarkable histological changes were

observed on the cerebellum.

Conflict of interest

The authors declared no conflict of interest.

References

1. Hinderling P H, Gundert-Remy U, Schmidlin O, et al. Integrated pharmacokinetics and pharmacodynamics of atropine in healthy humans. II: Pharmacodynamics. *J Pharm Sci.* 1985;74:711-7.
2. Grinspoon L, Bakalar J B. *Psychedelic drugs reconsidered*: Basic Books New York; 1979.
3. Landauer W. Cholinomimetic teratogens. V. The effect of oximes and related cholinesterase reactivators. *Teratology.* 1977;15:33-42.
4. Barceloux D G. *Medical toxicology of natural substances: foods, fungi, medicinal herbs, plants, and venomous animals*. Los Angeles, California: General and Introductory Medical Science: John Wiley and Sons; 2008.
5. Pennacchio M, Jefferson L, Havens K. *Uses and abuses of plant-derived smoke: Its ethnobotany as hallucinogen, perfume, incense, and medicine*. New York: Oxford University Press; 2010.
6. Robertson D, Low P A, Polinsky R J. *Primer on the autonomic nervous system*: Academic Press; 2011.
7. Holzman R S. The legacy of Atropos, the fate who cut the thread of life. *Anesthesiology.* 1998;89:241-9.
8. Bankole O O, Laoye B J, Sirjao M U, et al. Vitamin D 3 Receptor Activation Rescued Corticostriatal Neural Activity and Improved Motor Function in-D 2 R Tardive Dyskinesia Mice Model. *J Biomed Sci Eng.* 2015;8:520-30.
9. Scoville W B, Milner B. Loss of recent memory after bilateral hippocampal lesions. *J Neurol Neurosurg Psychiatry.* 1957;20:11-21.
10. Ferreira A R, Furstenau L, Blanco C, et al. Role of hippocampal M1 and M4 muscarinic receptor subtypes in memory consolidation in the rat. *Pharmacol Biochem Behav.* 2003;74:411-5.
11. Poulin B, Butcher A, McWilliams P, et al. The M3-muscarinic receptor regulates learning and memory in a receptor phosphorylation/arrestin-dependent manner. *Proc Natl Acad Sci U S A.* 2010;107:9440-5.
12. Picciotto M R, Higley M J, Mineur Y S. Acetylcholine as a neuromodulator: cholinergic signaling shapes nervous system

function and behavior. *Neuron*. 2012;76:116-29.

13. Stumpf DA. Cerebellar Disorders. In Rosenberg, RN (ed): *Comprehensive Neurology*. Raven Press, New York; 1991.

14. Xia G, McFarland K N, Wang K, et al. Purkinje cell loss is the major brain pathology of spinocerebellar ataxia type 10. *J Neurol Neurosurg Psychiatry*. 2013;84:1409-11.