

Squamous Cell Carcinoma of the Lateral Border of the Tongue in a Patient with Toxic Multinodular Goitre (Hyperthyroidism): A Case Report

Sarah Ibiyemi, Ibrahim Mogaji, Oluwaremilekun Dada

Department of Dental Services, Federal Medical Centre, Abeokuta, Ogun state, Nigeria.

Submitted 6 Aug 2018; Accepted 30 Sep 2018; Published 3 Oct 2018

Squamous cell carcinoma (SCC) of the oral cavity can mimic a myriad of ulcerative lesions in the mouth. This is particularly true for medically complex patients who due to their underlying systemic condition and multiple use of drugs, are prone to oral lesions. With increasing dental awareness, more patients are presenting early to the oral surgeons. The era of patients presenting first to the clinician with characteristic fungating solitary ulcer in the mouth with rocky hard submandibular lymph node involvement may be fast disappearing. The aim of the present report is to present a female patient with multiple focal area of erythema on the right lateral border of the tongue which though appeared innocuous but was discovered to be SCC after punch biopsy. High index of suspicion with proper attention to clinical details will be necessary for early diagnosis of SCC in the oral cavity, and therefore improve the overall prognosis of the patient.

Keywords: Goitre, hyperthyroidism, squamous cell carcinoma, tongue

Squamous cell carcinoma (SCC) is considered as one of the most common oral cancers (1). The tongue is one of the oral cavity sub sites associated most commonly with SCC. Previous studies have demonstrated that cancers of the tongue are distinct biologically and epidemiologically from other tumors of the oral cavity. Tongue cancers are associated with an increased proportion of patients who are women, aged under 40 years, and non-smokers (2). Most patients in this part of the world present in the late stage, and treatment is therefore usually palliative (3), but with increasing awareness about oral health and early presentation of patients, high index of suspicion and good clinical acumen is expected so that missed diagnosis from clinicians will not be an increasing cause for late intervention.

Case presentation

A 52 years old woman presented to the oral diagnosis clinic upon redness and discomfort on the

right lateral side of her tongue for 3 months duration. She has been diagnosed for toxic multinodular goiter about a year before at the endocrinology unit of this centre. She was on carbimazole (an antithyroid drug) 10 mg three times daily at the time of presentation.

She was conscious and alert, not pale, anicteric. She did not present any obvious respiratory or painful distress. A diffuse midline neck swelling (about 6 cm in its widest diameter) consistent with toxic multinodular goiter was observed. The vital signs were all within normal limits. She had no peripheral lymphadenopathy and no pedal edema. Extra-oral examination revealed no facial asymmetry, and submandibular lymph nodes were bilaterally palpable, freely mobile and not tender. Temporomandibular joints were bilaterally palpable, moved synchronously and were not tender. However, intraoral examination revealed an area of

*Correspondence: Department of Dental Services, Federal Medical Centre, Abeokuta, Ogun state, Nigeria.
E-mail: ibrahimtasnan@gmail.com

erythema located approximately around the middle third on the right lateral border of the tongue. There were 5 different focal spots that appeared more erythematous than the surrounding area. The widest of these spots was about 4 mm in diameter. The region was however indurate with mild tenderness. She also had an overdenture replacing lower right central incisor. She has been using denture for two years. The dentures were done by a general practitioner and they appeared well fabricated and fitted with no rocking movements.

A full blood count and differentials, also electrolytes and urea were ordered. A punch biopsy was preferred to minimize trauma and regarding the medical condition of the patient. Patient was advised to sparingly use the denture within the week as she insisted she could not do without it. Punch biopsy was planned a week after presentation while results for heamatological investigations were also expected.

The patient presented to the clinic a week after with vital signs being within normal limits. The lateral border of the tongue also did not appear differently from the day of first presentation though patient claimed to have complied with use of denture sparingly. Full blood counts and differentials were within normal range thereby ruling out agranulocytosis and neutropenia. Electrolyte and urea were also within normal limits.

After achieving anaesthesia by blocking the lingual nerve on the right side, a 4 mm metal punch was used for the biopsy. Two of the focal points of the erythema were chosen. One was taken within apparently normal tissue, the other was taken deep into area suspected to be the focal point of the lesion with induration. Heamostasis was achieved with digital pressure. One each 3.0 vicryl sutures were placed on the biopsy site. She was placed on 2% lignocaine gel to be applied using a pur-wrap directly on the site. 8 hourly 500 mg paracetamol tablet was also prescribed for 3 days. Biopsy tissue was preserved in 10% formalin and sent to the oral pathologist.

Histologic section revealed a densely collagenized connective tissue stroma infiltrated by invading cords, sheets and islands of neoplastic squamous epithelium (Figure 1). The neoplastic squamous epithelium exhibited cellular and nuclear hyperchromatism and increased nucleocytoplasmic ratio and also cellular and nuclear atypia (Figure 2). Some cells also exhibited vesicular nuclei. Also, chronic inflammatory cells predominantly lymphocytes, plasma cells, endothelial lined vascular channels and muscle tissue were observed. Histological diagnosis of moderately differentiated squamous cell carcinoma of the right lateral border of the tongue was made.

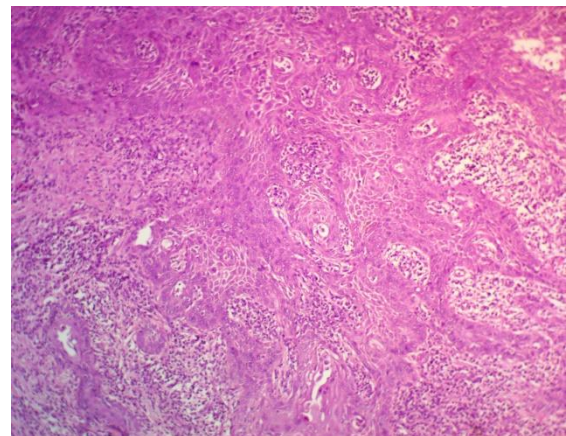


Figure 1. Photomicrograph showing sheets of neoplastic epithelium within the stroma. Some squamous cells exhibit nuclear and cellular pleomorphism, nuclear hyperchromatism and elaborate keratin (x100).

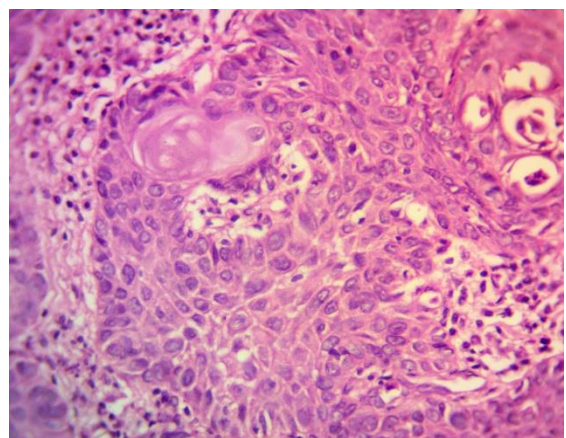


Figure 2. Photomicrograph of neoplastic epithelium. Cellular atypia and chronic inflammatory cells are apparent (x200).

Discussion

The patient with a previous history of hyperthyroidism and on medications posed a major diagnostic challenge. In addition, the presence of flanges of the denture around the area of the erythema made this look like chronic irritation from the denture. Studies have shown that chronic irritation from denture wearers have resulted in oral squamous carcinoma (4). The present patient had the denture changed three months before presentation when she noticed the erythematous area, on the suspicion that it was caused by the denture.

Another diagnostic challenge is the possibility of a drug induced erythema. Carbimazole which is an antithyroid drug, is a well-known medication used in the treatment of hyperthyroidism (5). Agranulocytosis is a recognized but rare and life-threatening side effect of carbimazole therapy, which usually occurs within the first 3 months of treatment (6) but manifestation can be delayed even to well over a year (7). The incidence of this particular side effect has been reported to range from 0.3% to 0.6% (6) and is associated with a mortality rate of 21.5% (8).

Clinically, patients usually present with fever (92%), sore throat (85%), painful mouth ulcer (15%), anal ulcer (8%), reduced immune response, and are prone to bacterial infections (9). However, non of these clinical features apart from the painful area of erythema were observed in our patient. Moreover, results of the full blood count showed no features of agranulocytosis or neutropenia.

Because of the induration of the lesion, SSC was suspected which was confirmed by the punch biopsy result. SSCs are usually solitary ulcers though could rarely be multifocal (10). The observation of multifocal area of erythema on the lateral border of the tongue in this patient may represent one of the rare cases reported in the literature.

This present case underscores the importance of methodical approach in achieving diagnosis based on a sound knowledge of the differentials. According to the literature, many cases of oral

malignant ulcerations were misdiagnosed as nonneoplastic lesions up to several months before the definite diagnosis was established (11-13). Valente et al. reported a case of SSC misdiagnosed as a denture-related traumatic ulcer (11). De Sant' Ana dos Santos et al. also reported misdiagnosis of lip SCC as actinic cheilitis (12). A case of gingival SCC appearing as an aphthous ulcer was also reported by Kumari et al. (13). This time elapsed between misdiagnosis and actual diagnosis might jeopardize patients' overall prognosis; therefore, attempts should be made to come to timely diagnosis via evidenced based approach and high index of suspicion. The golden rule to biopsy a lesion beyond 2 weeks in a site even after removal of irritating factor, etiology or proves refractory to local therapy cannot be over emphasized (14). The patient was therefore planned for partial glossectomy with neck dissection. The present report also emphasizes the importance of not always attributing oral lesions in medically complex patients as being due to the underlying medical condition(s) or drug use.

Conflict of interest

The authors declared no conflict of interest.

References

1. Taghavi N and Yazdi I. Prognostic factors of survival rate in oral squamous cell carcinoma: clinical, histologic, genetic and molecular concepts. *Arch Iran Med.* 2015;18:314-9.
2. Rusthoven K, Ballonoff A, Raben D, et al. Poor prognosis in patients with stage I and II oral tongue squamous cell carcinoma. *Cancer.* 2008;112:345-51.
3. Da Lilly-Tariah O B, Somefun A O, Adeyemo W L. Current evidence on the burden of head and neck cancers in Nigeria. *Head & Neck Oncology.* 2009;1:14.
4. Panat S, Aggarwal A, Chakarvarty A. Denture induced squamous cell carcinoma: A rare case report. *J Dent Sci Rehabil.* 2012;3:42-4.
5. Cooper D S. Antithyroid drugs. *N Engl J Med.* 2005;352:905-17.s
6. Tajiri J, Noguchi S, Murakami T, et al. Antithyroid drug-induced agranulocytosis. The usefulness of routine white blood cell count monitoring. *Arch Intern Med.* 1990;150:621-4.

7. Mohan A, Joseph S, Sidharthan N, et al. Carbimazole-induced agranulocytosis. *J Pharmacol Pharmacother.* 2015;6:228-30.
8. Cooper D S, Goldminz D, Levin A A, et al. Agranulocytosis associated with antithyroid drugs. Effects of patient age and drug dose. *Ann Intern Med.* 1983;98:26-9.
9. Mahant S, Shobhane U, Mahant P. Carbimazole induced agranulocytosis with life-threatening complications, tremendous response with granulocyte-colony stimulating factor. *Medical Journal of Dr. DY Patil University.* 2016;9:79-81.
10. Wood N K, Goaz P W, Alling C C, Differential diagnosis of oral lesions. Mosby St. Louis:1991.
11. Valente V B, Takamiya A S, Ferreira L L, et al. Oral squamous cell carcinoma misdiagnosed as a denture-related traumatic ulcer: A clinical report. *J Prosthet Dent.* 2016;115:259-62.
12. De Sant'ana Dos Santos F, Ispier M A, Pereira Novo-Neto J, et al. Misdiagnosis of lip squamous cell carcinoma. *RSBO.* 2012;9:114-8.
13. Kumari P S, Kumar G P, Bai Y D, et al. Gingival squamous cell carcinoma masquerading as an aphthous ulcer. *J Indian Soc Periodontol.* 2013;17:523-6.
14. Hershita S S, Nancy C, Monika P, et al. Biopsy- A vision of life. *International Journal of Contemporary Medical Research.* 2016;3:1734-7.