

Effects of *Hibiscus rosa-sinensis* Linn. Flower Extract on Epididymis, Prostate and Seminal Vesicles of Male Rats

Bunga Tiara Carolin^{1*}, Shinta Novelia¹, Sri Nita²

1. Faculty of Health Sciences, Universitas Nasional, Jakarta, Indonesia.

2. Biomedical Sciences, Faculty of Medicine, Universitas Sriwijaya, Palembang, Indonesia.

Submitted 21 Jul 2019; Accepted 2 Aug 2019; Published 26 Aug 2019

Hibiscus rosa-sinensis Linn. is one of medicinal plants in Indonesia that is used as a male contraceptive. Hibiscus flower contains flavonoids that can decrease testosterone. The purpose of this study was to determine the effects of hibiscus flower extract on the weight of the epididymis, prostate and seminal vesicles, and the thickness of the cauda epididymal epithelium, in male rats. 25 male Sprague Dawley® rats aged 60-70 days and weighing 200-210 g were subdivided into 5 groups of 5 animals each, and were treated with 0 (control), 200, 300, 400, and 500 mg/kg body weight of hibiscus flower methanolic extract for 30 days. The results showed a decrease in weight of the epididymis in the treatment groups ($P < 0.001$). Also, there was also a decrease in the thickness of the cauda epididymal epithelium ($P = 0.021$), as well as the weight of the prostate and seminal vesicles in treatment groups in comparison with the control group ($P = 0.001$). Therefore, hibiscus flower extract affected the weight of the epididymis, prostate and seminal vesicles and the thickness of cauda epididymal epithelium.

Keywords: Hibiscus flower, epididymis, cauda epididymal epithelium, prostate, seminal vesicles

Fertility control is a public health issue of the world (1). About 90% of those using contraception in the world are women (1). The increasing number of population is an important issue for Indonesia (2). One of the efforts to overcome the problem of population growth and maternal mortality due to pregnancy was using contraceptives (2). Limitations in choosing contraceptive methods are one of the main reasons for the low participation of men in using contraception (3). The current methods of male contraception that are most common in society are condoms and vasectomy (4). Both of which represent 20-30% of all contraceptives in the United States. Efforts are being made to develop new methods of male contraception. The extensively tested approach involves the administration of testosterone, which acts as a contraceptive by

suppressing luteinizing hormone (LH) and follicle-stimulating hormone (FSH) suppression from the pituitary gland (5).

Indonesia has various types of medicinal plants that have antifertility potential (3). Although many plants have been shown to prevent the birth of babies, only a few plants have so far been studied for antifertility properties. One of the plants that is expected to have antifertility activity is hibiscus flower (*Hibiscus rosa-sinensis* Linn.)

In Indonesia hibiscus is known to be effective against mumps, whiteness, sprue, slimy cough, inflammation of the respiratory tract, and malaria fever. Hibiscus flower was also reported to have hypoglycemic and antifertility effects (6, 7). Its beneficial effects may be due to the presence of various compounds namely tannins, alkaloids, triterpenoids, flavonoids, taraxeryl acetates,

*Correspondence: Faculty of Health Sciences, Universitas Nasional, Jakarta, Indonesia. E-mail: bungacarolinmbmd@gmail.com

polyphenols, saponins, hibisetin, cyanidine, cyanidine glycosides, quercetin, cyanidine diglucosides, Ca-oxalates, bitter substances, and peroxidases. Flavonoids have a variety of bioactivity, including antifertility (8).

The purpose of this study was to determine the effect of hibiscus flower extract on epididymis, prostate and seminal vesicles of male rats.

Materials and Methods

Animals and study design

Twenty five white male rats Sprague Dawley® strain aged 60-70 days and weighing 200-210 g were obtained from the Bandung Institute of Technology, and were cared according to the institutional and national guide for the care and use of laboratory animals.

The effect of 30 days oral treatment with hibiscus flower extract on the thickness of cauda epididymial epithelium, as well as epididymis, prostate and seminal vesicles weight was investigated in five groups (control group treated with 1% carboxy methyl cellulose (CMC), and groups 1-4 who received 200, 300, 400, and 500 mg/kg body weight hibiscus flower extract, respectively) of 5 rats each.

Plant extract preparation

Maceration extraction method was performed by using methanol as solvent. 3.5 kg fresh hibiscus flowers were obtained from the field. 400 g dry weight was obtained from those flowers. The dried flowers were inserted into the extractor tube, and then completely immersed in methanol. Then the top was closed to prevent the entry of impurities and solvent evaporation. Soaking was done for 48 h with several stirrings. The liquid extract was then evaporated with rotary evaporator, and dried using a hair dryer until reaching a thickness similar to a pasta, and weighing 90 g which correspond to an output of 22.5%.

Chromatography and compounds determination

A thin layer chromatography (TLC) test was performed to determine the active compound

classes. Briefly, 1 ml methanol solvent was added to 1 mg extract, and mixed well. Then the diluted extract was placed on a F₂₅₄ silica gel plate by using a capillary pipette, developed with an appropriate phase of motion, and was sprayed with H₂SO₄ solution. Afterward, the silica plate was transferred on the hot plate, and colored spots appeared.

Preparation of epididymal tissue and histopathological staining

The epididymal tissue of the cauda was cut into small pieces, and placed in physiological serum (NaCl 0.9%), then fixed for 1 day in 10% formalin. Fully fixed organ samples were cut into 0.5 cm thick pieces, and then inserted in a tissue cassette for automatic tissue processing through successive dehydration with alcohol, and were cleared overnight with xylol. Then, the cauda epididymis pieces were paraffin embedded and cut into 3 µm thick slices using microtome. Epididymal cauda slices were stained with eosin and hematoxylin.

Statistical analysis

Normality and homogeneity tests were performed as a requirement to perform Anova (9) and Duncan test. $P < 0.05$ was considered as statistically significant.

Results

Chromatography analysis of hibiscus flower extract

Analysis of methanolic extract of hibiscus flower by TLC using methanol: ethyl acetate (1:9) as eluent revealed the presence of purplish red spots with R_f value of 0.46 indicating the presence of flavonoids.

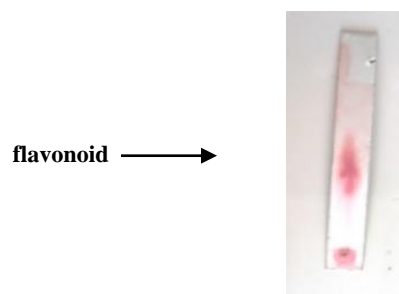


Figure 1. Result of TLC test on hibiscus flower extract.

Table 1. Weight of epididymis among treatment groups

Groups	N	Weight of epididymis (g) $\bar{x} \pm$ SD	P-Value
Control	5	0.466 \pm 0.036 a	<0.001
1	5	0.437 \pm 0.016 ab	
2	5	0.437 \pm 0.021 ab	
3	5	0.408 \pm 0.127 bc	
4	5	0.387 \pm 0.023 c	
Groups 1-4 correspond to 200, 300, 400, and 500 mg/kg body weight hibiscus flower extract treatment, respectively. The numbers followed by the same lower case are not significantly different in the Duncan advanced test (P <0.05).			

Effect of hibiscus flower extract on the weight of epididymis

Hibiscus flower extract treatment for 30 days on 25 rats showed a decrease of epididymis weight. Table 1 shows that the average weight of the epididymis decreased with increasing doses of hibiscus extract. ANOVA statistical test revealed a significant difference of mean weight of epididymis ($P < 0.001$) between treatment groups, meaning that giving hibiscus flower extract has an effect on the weight of epididymis. In order to evaluate the significance between the treatment groups, a further Duncan assay was performed which showed a decrease in epididymal weight in groups 1 and 2 in comparison with the control group, but the results were not significantly different while groups 3 and 4 showed a significant difference in comparison with control group. Also, the weight of the epididymis decreased in group 3 and differed significantly with groups 1 and 2 and control group.

Effect of hibiscus flower extract on epididymis cauda

The effect of hibiscus flower on cauda epididymial epithelium thickness of male rats after treatment for 30 days showed a decrease of epididymal epithelium thickness. Table 2 showed that the average thickness of the epididymal epididymis cauda decreased with increasing doses of hibiscus extracts. ANOVA statistic test

Table 2. Weight of epididymis among treatment groups

Groups	N	Epididymal cauda thickness (μm) x̄± SD	P-Value
Control	5	4.817 ± 0.499 a	0.021
1	5	4.800 ± 0.579 a	
2	5	4.135 ± 0.712 ab	
3	5	3.937 ± 0.913 ab	
4	5	3.496 ± 0.521 b	
The numbers followed by the same lower case are not significantly different in the Duncan advanced test (P <0.05).			

results showed a P value = 0.021. This suggests that there was a difference in mean thickness of epididymal epithelium cauda between treatment groups. Duncan's follow-up test showed that the thickness of the epididymal epithelium in group 4 was significantly different from control group. In groups 1, 2, and 3 the epithelial epididymis cauda thickness decreased but was not significantly different from control group. Similarly, in group 4, there was a marked decrease in epididymal epithelium thickness in comparison with groups 2 and 3. There was a greater decrease in cauda epididymal epithelium thickness in group 4 in comparison with groups 1, 2, and 3, and was significantly different from the control group. The thickening of the epididymal epididymal cauda can be seen in Figure 2.

Table 3. Weight of epididymis among treatment groups

Groups	Prostate and seminal vesicles weight (g) $\bar{x} \pm$ SD	P-Value
Control	1.811 \pm 0.218 a	0.001
1	1.565 \pm 0.176 ab	
2	1.459 \pm 0.500 bc	
3	1.290 \pm 0.247 c	
4	1.265 \pm 0.191 c	
The numbers followed by the same lower case are not significantly different in the Duncan advanced test (P < 0.05).		

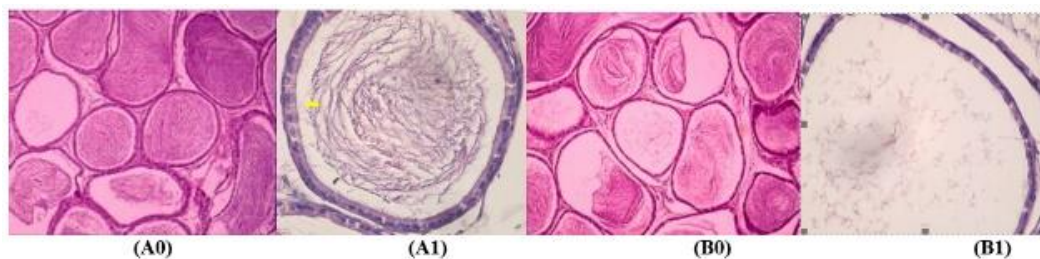


Figure 2. Histology of cauda epididymal epithelium. A0: control group with magnification x10; A1: control group with magnification x40; B0: treatment group with dose 500 mg/kg BW with magnification x10; B1: treatment group with dose 500 mg/kg BW with magnification x40. Yellow bar represents a thick cauda epididymal epithelium.

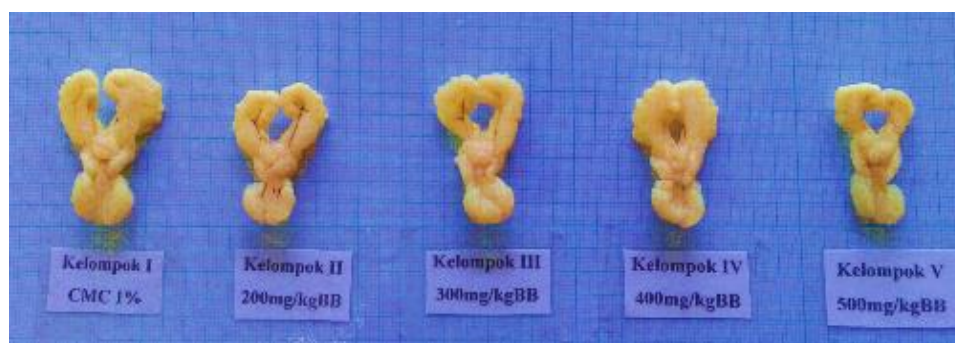


Figure 3. Seminal vesicles and prostates from different treatment groups. From left to right: representative prostates belonging to control and groups 1 to 4.

The Effect of hibiscus flower extract on prostate gland and seminal vesicles weight

The effect of hibiscus flower extract on the weight of the prostate gland and seminal vesicle of male rats was evaluated after treatment for 30 days. Table 3 represents mean weight of prostate gland and intermediate seminal vesicles.

The mean weight of the prostate and seminal vesicles decreased with increasing doses of hibiscus flower extract. A significant difference in mean weight of the prostate and seminal vesicles was observed between treatment groups ($P = 0.001$). Figure 3 illustrates the decrease of weight of prostate and seminal vesicles starting from control group (CMC 1%), followed by treatment groups 1-4.

In order to analyze intergroup significance, Duncan's follow-up test was performed and revealed no significant difference of weight decrease between group 1 and control group, while groups 2, 3 and 4 showed a significant difference with control group. In group 4 there was a greater decrease in prostate

weight and seminal vesicles in comparison with groups 1, 2, and 3.

Discussion

Hibiscus rosa-sinensis Linn. flower extract treatment on male rats for 30 days caused epididymial weight reduction in comparison with controls. This effect begun to appear at 400 mg/kg BW. This finding is in accordance with the report of Kumar et al. (8) who found a significant decrease in epididymal weight in animals treated with hibiscus flower extract at a dose of 200 mg/kg BW. Also, Jana et al. have reported the effects of hibiscus flower extract treatment, at doses of 150 and 300 mg/kg BW for 60 days, but the changes were only temporary and reversible (10). The occurrence of severe epididymal reduction is thought to be due to the presence of flavonoids in the hibiscus extract. This flavonoid content causes hypothalamic and pituitary failure to secrete gonadotropin-releasing hormone (GnRH) (11). Furthermore, the pituitary failure in the synthesis of FSH and LH may occur,

causing leydig cell failure to perform testosterone synthesis (11). Epididymis weight loss may be due to the decrease of testosterone that controls the function of epididymis. Decrease of testosterone can induce changes in the epididymal duct, and degeneration of epididymal epithelium. The present study also showed that hibiscus flower extract caused a decrease of thickness of cauda epididymial epithelium at 500 mg/kg BW dose. The thickening of the cauda epididymial epithelium is suspected to be due to treatment with hibiscus flower extract that contains flavonoid compounds that may cause testosterone level decrease (12). Flavonoids are estrogenic compounds that can occupy estrogen receptors in the body (13), and cause a decrease of FSH secretion and inhibit LH production. As LH secretion is important for growth and control of the number of leydig cells, its inhibition causes a decrease of the secretion of testosterone (14,15). This study showed the presence of flavonoids among the compounds present in the hibiscus flower, which has a variety of bioactivities including antifertility (16).

Steroidogenesis that leads to testosterone synthesis, takes place in leydig cells. If the number or function of these cells is reduced, then testosterone production will also be reduced (17). Once secreted, the testosterone is then bound by androgen binding protein (ABP) secreted by sertoli cells. Because testosterone decreases, the synthesis of ABP also decreases, causing decreased transport of testosterone to the epididymis which causes the atrophy of epithelial cells. ABP acts as a carrier compound for androgens in the seminiferous tubules and epididymis (18).

The present study also showed that *Hibiscus rosa-sinensis* Linn. extract can induce a decrease in the weight of the prostate gland and seminal vesicles at a dose of 300 mg/kg BW. Decreased testosterone induced by flavonoid contents of hibiscus flower extract will decrease the level of 5 α -dehydroreductase. This decrease will decrease dihydrotestosterone (DHT) levels in the prostate

gland. Decreased levels of DHT will inhibit the growth of epithelial cells of the prostate gland, thereby reducing the thickness of epithelial cells and the weight of the prostate gland (19). In addition, it also disrupts the process of growth and development of other accessory organs that cause cell atrophy and weight loss of seminal vesicle organs (20). If testosterone levels decrease, the cells of the seminal vesicle organ become atrophied and the entire gland will become small, and seminal vesicles function regarding semen volume, coagulation and fructose sources, also decreases (21).

Further research is needed to explore the effect of hibiscus flower extract on other reproductive organs such as epididymis (caput and corpus), vas deferens and cowper glands.

Conflict of interest

The authors declared no conflict of interest.

References

1. Joshi S C, Sharma A, Chaturvedi M. Antifertility potential of some medicinal plants in males: an overview. *Int J Pharm Pharm Sci.* 2011;3:204-17.
2. Seiff A. Indonesia to revive national family planning programme. *Lancet.* 2014;383:683.
3. Tulsiani D R and Abou-Haila A. Biology of male fertility control: an overview of various male contraceptive approaches. *Minerva Ginecol.* 2015;67:169-83.
4. Plana O. Male Contraception: Research, New Methods, and Implications for Marginalized Populations. *Am J Mens Health.* 2017;11:1182-9.
5. Gill-Sharma M K. Testosterone Retention Mechanism in Sertoli Cells: A Biochemical Perspective. *Open Biochem J.* 2018;12:103-12.
6. Idris M H, Budin S B, Osman M, et al. Protective role of *Hibiscus sabdariffa* calyx extract against streptozotocin induced sperm damage in diabetic rats. *Excli j.* 2012;11:659-69.
7. Peng C H, Chyau C C, Chan K C, et al. *Hibiscus sabdariffa* polyphenolic extract inhibits hyperglycemia, hyperlipidemia, and glycation-oxidative stress while improving insulin resistance. *J Agric Food Chem.* 2011;59:9901-9.
8. Srivastav A, Chandra A, Singh M, et al. Inhibition of hyaluronidase activity of human and rat spermatozoa in vitro and antispermatic activity in rats in vivo by *Terminalia chebula*, a flavonoid rich plant. *Reprod Toxicol.* 2010;29:214-24.
9. Kao L S and Green C E. Analysis of variance: is there a difference in means and what does it mean? *J Surg Res.* 2008;

144:158-70.

10. Jana T, Das S, Ray A, et al. Study of the effects of hibiscus-rosa-sinensis flower extract on the spermatogenesis of male albino rats. *J Physiol and Pharmacol Adv*. 2013;3:167-71.

11. Ramaswamy S and Weinbauer G F. Endocrine control of spermatogenesis: Role of FSH and LH/ testosterone. *Spermatogenesis*. 2014;4:e996025.

12. Puranik N V, Srivastava P, Bhatt G, et al. Determination and analysis of agonist and antagonist potential of naturally occurring flavonoids for estrogen receptor (ERalpha) by various parameters and molecular modelling approach. *Sci Rep*. 2019;9:7450.

13. Benghuzzi H, Tucci M, Mohamed A, et al. Differential Histopathological Assessment of Testicular Function Upon Long-Term Exposure to Sustained Delivery of Testosterone and Dihydrotestosterone. *Biomed Sci Instrum*. 2018;54:138-44.

14. Olesen I A, Joensen U N, Petersen J H, et al. Decrease in semen quality and Leydig cell function in infertile men: a longitudinal study. *Hum Reprod*. 2018;33:1963-74.

15. Olivares-Vicente M, Barrajon-Catalan E, Herranz-Lopez M, et al. Plant-Derived Polyphenols in Human Health: Biological Activity, Metabolites and Putative Molecular Targets. *Curr Drug Metab*. 2018;19:351-69.

16. Minabe S, Sato M, Inoue N, et al. Neonatal Estrogen Causes Irreversible Male Infertility via Specific Suppressive Action on Hypothalamic Kiss1 Neurons. *Endocrinology*. 2019;160:1223-33.

17. Savchuk I, Soder O, Svechnikov K. Mouse leydig cells with different androgen production potential are resistant to estrogenic stimuli but responsive to bisphenol a which attenuates testosterone metabolism. *PLoS One*. 2013;8:e71722.

18. Huang H F, Pogach L, Giglio W, et al. GnRH-A induced arrest of spermiogenesis in rats is associated with altered androgen binding protein distribution in the testis and epididymis. *J Androl*. 1992;13:153-9.

19. Zager M G and Barton H A. A multiscale, mechanism-driven, dynamic model for the effects of 5alpha-reductase inhibition on prostate maintenance. *PLoS One*. 2012;7:e44359.

20. Yarkin E, Bernoulli J, Talvitie E M, et al. Inflammation and epithelial alterations in rat prostate: impact of the androgen to oestrogen ratio. *Int J Androl*. 2009;32:399-410.

21. Arafa M, Henkel R, Agarwal A, et al. Correlation of oxidation-reduction potential with hormones, semen parameters and testicular volume. *Andrologia*. 2019;51:e13258.