

Delayed Diagnosis of Infective Endocarditis Complicated With Stroke

Hanee Mehboob Mohamed, Henry Anselmo Mayala*

Muhimbili National Hospital, Jakaya Kikwete Cardiac Institute, Tanzania.

Submitted 16 May 2016; Accepted 19 Jun 2016; Published 13 Jul 2016

Infective endocarditis can complicate with ischemic stroke. Neurological complications develop in 20–40% of all patients with infective endocarditis. These are mainly due to vegetation embolism. This report represents a case of 30 years old female patient who presented with features of heart failure New York Heart Association (NYHA) class IV with infective endocarditis and left hemiparesis. On examination at admission, she was conscious, afebrile, orthopneic, tachypneic, had warm extremities, tinge of jaundice, finger and toe clubbing grade 4, and moderate pretibial edema. Her blood pressure was 107/54 mm Hg and had heart rate of 125 beats per minute. She had cardiomegaly with apex shifted to 6th intercostal space, soft s1 loud p2 and apical pansystolic murmur grade 3 radiating to axilla of MR, pansystolic murmur left lower sternal border of TR and early diastolic murmur of AR. There was mild ascites, hepatosplenomegaly, fine bilateral bibasal crepitations and left hemiparesis. Echocardiogram showed severe mitral regurgitation, moderate aortic regurgitation and multiple vegetations. This case is presented to assert the importance of early diagnosis of infective endocarditis to prevent the occurrence of neurological sequelae. The rapid diagnosis using Dukes criteria of infective endocarditis is of paramount importance to prevent or reduce neurological sequelae. This patient had findings of splenomegaly and clubbing suggesting long standing endocarditis that could have been identified early.

Keywords: Infective endocarditis, stroke, neurological complications

Infective endocarditis (IE) is defined as an infection of the endocardial surface of the heart, which may include one or more heart valves, the mural endocardium, or a septal defect. Its intracardiac effects include severe valvular insufficiency, which may lead to intractable congestive heart failure and myocardial abscesses. If left untreated, IE is generally fatal.

Neurological complications develop in 20–

40% of all patients with infective endocarditis. These are mainly due to vegetation embolism (1). It is very important to diagnose infective endocarditis early and treat to prevent or reduce neurological sequelae.

Endocarditis has evolved into several variations, keeping it near the top of the list of diseases that must not be misdiagnosed or overlooked. Endocarditis can be broken down into

*Correspondence: Muhimbili National Hospital, Jakaya Kikwete Cardiac Institute, Tanzania E-Mail: mayalahenry29@gmail.com

the following categories:

- Native valve endocarditis (NVE), acute and subacute
- Prosthetic valve endocarditis (PVE), early and late
- Intravenous drug abuse (IVDA) endocarditis
- Other terms commonly used to classify types of IE include pacemaker IE and nosocomial IE (NIE).
- The classic clinical presentation and clinical course of IE has been characterized as either acute or subacute. Indiscriminate antibiotic usage and an increase in immunosuppressed patients have blurred the distinction between these 2 major types. However, the classification still has clinical merit.
- Acute NVE frequently involves normal valves and usually has an aggressive course. It is a rapidly progressive illness in persons who are healthy or debilitated. Virulent organisms, such as *S. aureus* and group B streptococci, are typically the causative agents of this type of endocarditis. Underlying structural valve disease may not be present.
- Subacute NVE typically affects only abnormal valves. Its course, even in untreated patients, is usually more indolent than that of the acute form and may extend over many months. Alpha-hemolytic streptococci or enterococci, usually in the setting of underlying structural valve disease, typically are the causative agents of this type of endocarditis.

Case Report

This is a case of 30 years old female patient from Morogoro, Para 3 living 3 with 4 months old last child, admitted with complaints of difficulty in breathing and palpitations for last four months. The history of difficulty in breathing was of gradual onset, increasing in severity, initially on exertion, later even at rest and history of paroxysmal nocturnal dyspnea. This was accompanied with lower limb swelling. These symptoms were sugges-

tive of New York Heart Association (NYHA) class IV heart failure. There was history of reduced urine frequency but no history of fever or cough. History of sore throat a year ago but no history of joint pains was reported. This was her index admission. During her course of illness, she visited peripheral health center twice where she was told to also have anemia. Put on medications that included lasix and other anti-heart failure treatments, she attended outpatient follow up irregularly and was not adherent on medications due to poor affordability. She was a standard 6 leaver, married and worked as a peasant.

On examination at admission, she was conscious, afebrile, orthopneic, tachypneic, had warm extremities, tinge of jaundice, finger and toe clubbing grade 4, and moderate pretibial edema. Her blood pressure was 107/54 mm Hg and had heart rate of 125 beats per minute. Apex shifted to 6th intercostal space, soft s1 loud p2 and apical pansystolic murmur grade 3 radiating to axilla of MR, pansystolic murmur left lower sternal border of TR and early diastolic murmur of AR. There was mild ascites, hepatosplenomegaly, fine bilateral bibasal crepitations and left hemiparesis. The working diagnosis was rheumatic heart disease with infective endocarditis in heart failure NYHA IV presenting with ischemic stroke and pneumonia.

Blood work-up showed; WBC (K/UL): 20.2, Hb level (g/dl): 7.15, Platelets (K/UL): 71, Albumin (g/L): 25, Na (mmol/l): 135, K (mmol/l): 5.3, Creatinine (mmol/l): 94.3, BUN (mmol/l): 7.1, ALT (U/L): 220, AST (U/L): 963, INR: 1.44. Blood culture results showed no growth. Chest radiograph showed features suggestive of left ventricular failure. ECG showed left bundle branch block with heart rate of 135 beats/min. ECHO showed dilated left ventricle (5.9 cm), left atrium (5.0 cm), multiple small vegetations on the anterior mitral leaflet, on aortic leaflets and on septal tricuspid leaflet. MR

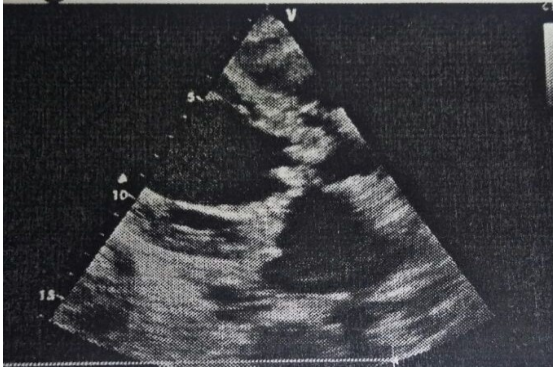


Figure 1. Echocardiogram of the patient.

maximum PG 91.35 mm Hg (severe eccentric mitral regurgitation), AV Vmax 2.45 m/s (mild aortic stenosis), AR PHT 310 ms (moderate aortic regurgitation), RVSP 44.33 mm Hg with moderate tricuspid regurgitation (Figure 1).

Progress in ward

She was started on intravenous X-pen 5MU 6 hourly, intravenous gentamycin 60 mg twice daily, intravenous frusemide 40 mg daily and tablets isosorbide mononitrate 10 mg twice daily. On follow-up, due to falling blood pressure, intravenous infusion of dobutamine 250 mg in 250 ml of normal saline at 10 ml per hour was added. The chest examinations revealed bronchial breath sounds and left inter scapular coarse crepitations and still congested liver. Intravenous frusemide was then increased to 60 mg twice daily, aldactone tablets 25 mg daily, enalapril tablets 2.5 mg daily and intravenous ampicillin and cloxacillin was started due to suspicion of staphylococcus endocarditis. She received the intravenous antibiotics for 6 weeks. Her hemodynamics improved significantly. She received physiotherapy for the hemiparesis. She has now been planned for definitive MVR and AVR with tricuspid annuloplasty.

Discussion

This is a case of infective endocarditis with neurological complication of ischemic parietal

stroke that was of recent onset. This patient had findings of splenomegally and clubbing suggesting long standing endocarditis that could have been identified early. Thrombocytopenia is also a risk marker of increased mortality in patients with native valve left-sided infective endocarditis (2).

Several factors including vegetation size ≥ 3 cm, *staphylococcus aureus* infection, mitral valve involvement and anticoagulant therapy have been associated with occurrence of neurological complications with overall higher mortality (3, 4). This patient had mitral valve involvement and was treated for staphylococcal infection. The average age of patients with neurological complications being 37.4 ± 5.8 years (5).

Blood-culture negative infective endocarditis is usually a consequence of prior antibiotic administration or infection with fastidious organisms with limited proliferation under conventional culture conditions (6). Antibiotics were initiated early at admission and no culture results were obtained.

Early surgery is recommended for patients with complicated infective endocarditis because it is independently associated with lower risk of in-hospital mortality especially in heart failure (7, 8)

Conflict of interests

The authors declared no conflict of interests.

References

1. Thuny F, Avierinos J-F, Tribouilloy C, et al. Impact of cerebrovascular complications on mortality and neurologic outcome during infective endocarditis: A prospective multicentre study. *Eur Heart J*. 2007;28:1155-61.
2. Ferrera C, Vilacosta I, Fernandez C, et al. Usefulness of thrombocytopenia at admission as a prognostic marker in native valve left-sided infective endocarditis. *Am J Cardiol*.
3. Garcia-Cabrera E, Fernandez-Hidalgo N, Almir-

ante B, et al. Neurological complications of infective endocarditis: Risk factors, outcome, and impact of cardiac surgery: A multicenter observational study. *Circulation*.127:2272-84.

4. Grecu N, Tiu C, Terecoasa E, et al. Endocarditis and stroke. *Maedica (Buchar)*.9:375-81.

5. Yameogo N V, Seghda A, Kagambega L J, et al. [neurological complications of infective endocarditis in burkina faso. Clinical features, management and evolutionary profile.]. *Ann Cardiol Angeiol (Paris)*.

6. Brouqui P, Raoult D. New insight into the diag-

nosis of fastidious bacterial endocarditis. *FEMS Immunol Med Microbiol*. 2006;47:1-13.

7. Galvez-Acebal J, Almendro-Delia M, Ruiz J, et al. Influence of early surgical treatment on the prognosis of left-sided infective endocarditis: A multicenter cohort study. *Mayo Clin Proc*.89:1397-405.

8. Malhotra A, Rayner J, Williams T M, et al. Infective endocarditis: Therapeutic options and indications for surgery. *Curr Cardiol Rep*. 2014;16:1-6.