

Fibrous Dysplasia of the Maxillofacial Region, a Review of 134 cases at Lagos University Teaching Hospital, Lagos, Nigeria

Olujide Soyele¹, Ramat Oyeunmi Braimah^{2*}, Abdurrazaq Taiwo³, Adebayo Ibikunle², Micah Gbotolorun⁴

1. Department of Oral & Maxillofacial Surgery and Oral Pathology, Obafemi Awolowo University Teaching Hospital Ile-Ife, Osun State, Nigeria.

2. Department of Dental and Maxillofacial Surgery, Usmanu Danfodiyo University Teaching Hospital, Sokoto, Nigeria.

3. Department of Surgery, College of Health Sciences, Usmanu Danfodiyo University Sokoto, Nigeria.

4. Department of Oral and Maxillofacial Surgery, College of Medicine, University of Lagos. Nigeria.

Submitted 7 Jun 2017; Accepted 26 Jul 2017; Published 26 Aug 2017

Fibrous dysplasia (FD) belongs to a group of lesions known as fibro osseous lesions (FOL) whereby normal bone is replaced with fibrous tissue containing abnormal bone or cementum. FOL are the most frequent and the most difficult lesions to diagnose, as they share overlapping spectrum of clinicopathological, radiological, and immunological characteristics. In this retrospective study of 134 maxillofacial FD cases diagnosed histologically in the department of Oral Biology and Oral Pathology during the period of 1970 to 2009 at the Lagos University Teaching Hospital, Idi-araba, Lagos, haematoxylin and eosin, as well as Masson's trichrome, and AgNOR staining were used to confirm the diagnosis of FD. FD cases represented 44.4% of FOL seen during the study period. FD was most commonly found in the age group of 10-19 years, where 69 cases (51.5%) were observed with a mean age of 18.85 ± 7.22 years. FD was observed more frequently in females with a female to male ratio of 1.44: 1. A relatively high proportion of mixed bone trabeculae was present in FD. FD was more commonly observed in the maxilla. Mixed bone trabeculae pattern seems to be a better predictor of FD.

Keywords: AgNOR staining, fibrous dysplasia, fibro osseous lesions, mixed bone trabeculae

Fibrous dysplasia (FD) is defined as a benign lesion, presumably developmental in nature, characterized by the presence of nonspecific fibrous connective tissue with a characteristic whorled pattern and containing trabeculae of immature non-lamellar bone (1-2). It is widely considered to be a hamartomatous or developmental malformation (3). It presumably results from an idiopathic arrest in maturation of bone at the woven bone stage and usually occurs within a single bone (monostotic) but may be found to affect multiple

bones (polyostotic) (4-5).

They belong to a group of lesions known as fibro-osseous lesions (FOL) whereby normal bone is replaced with fibrous tissue containing abnormal bone or cementum (6-7). Maxillofacial FOL are poorly defined heterogeneous group of lesions affecting the jaws and other craniofacial bones. They are characterized by the replacement of bone with a benign connective tissue matrix with varying degree of mineralization in the form of woven/lamellar bone or cementum-like round

*Correspondence: Department of Dental and Maxillofacial Surgery, Usmanu Danfodio University Teaching Hospital, Sokoto, Sokoto State, Nigeria. E-mail: robdeji@yahoo.com

acellular intensely basophilic structures (8-9). Generally, they show similar clinical, radiographic, and histologic characteristics, and are therefore difficult in diagnosis and management (10-11).

Clinical manifestations of FD of the jaws include jaw swelling, facial disfiguration (Figure 1), and occlusal derangement that result in significant cosmetic and functional disturbances in the affected patient (12-13).

The need to investigate this category of FOL regarding their clinico-pathological features as well as application of histo-chemical markers in this environment arose from previous reports on their abundance and difficulties in their diagnosis, as they share overlapping spectrum of clinico-pathological, radiological and immunological characteristics. Two histo-chemical markers have been selected to investigate these lesions (Masson's trichrome, and AgNOR staining). It has been established from the literature that Masson's trichrome staining has specific affinity for collagen tissues such as bone, muscle and cartilage. Since collagen is a major constituent of bone, and that the arrangement of collagen differs between matured (lamellar) and immature (woven) bone, the staining will impart different colour on the collagen (14).

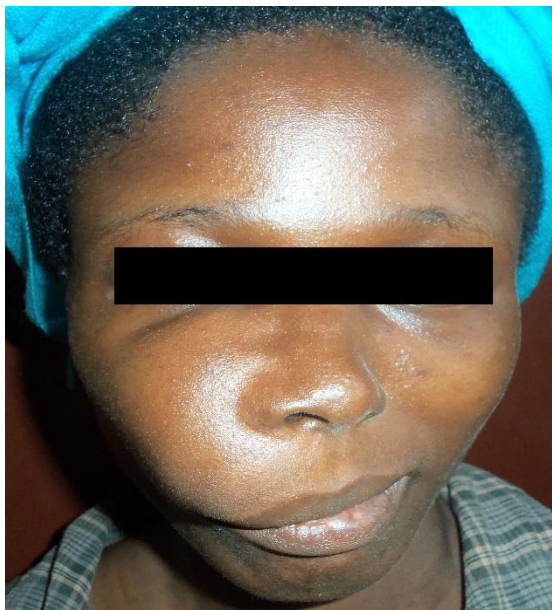

Figure 1. Clinical image of FD showing facial disfigurement.

AgNOR staining is an accurate and easily performed technique. Studies using this technique have suggested that quantitative analysis of AgNOR can be useful in estimating proliferative activity of neoplasms in surgical pathology. Specifically, it has been utilised as a diagnostic tool in comparing the proliferating activities of FD and ossifying fibroma (15).

The aim of this study was to review the clinico-pathologic, radiological pattern and histochemical features of maxillofacial FD at the Lagos University Teaching Hospital, Idi-Araba, Lagos, Nigeria.

Materials and methods

Study design

This study was carried out at the Lagos University Teaching Hospital, Idi-araba, Lagos, which is one of the foremost tertiary health care institution in Nigeria. It was a retrospective study of cases of histologically diagnosed maxillofacial FD in the department of Oral Biology and Oral Pathology during the period from 1970 to 2009. Lagos state is cosmopolitan with an estimated population of 9.5 million (National Population Commission of Nigeria 2006). It consists of people from diverse ethnic groups that are involved in inter-ethnic and mixed marriages. The land area making up this state is bounded by Ogun state in the North and East, the Atlantic Ocean in the South, and the republic of Benin in the West. Record of oral biopsies of FD cases of oral maxillofacial bone tumors were retrieved for analysis. Approval for this study was sought and obtained from the ethical committee of Lagos University Teaching Hospital for use of the past medical/dental records of material of subjects used for the study. All cases of FD in the maxilla or mandible with complete clinical and radiological data, all cases of FD with complete record of histological materials and data, all cases of FD that were centrally located in the jaws, and all cases of FD that have been reconfirmed histologically after review, were included in this

study. Cases not reconfirmed histologically as FD after review, and cases for which histological materials such as paraffin blocks, could not be retrieved, were excluded.

Data collection tools and techniques

Bio-data and clinical parameters such as information on age, sex and site of each lesion, as well as radiographic information, which consisted of lesional border and bone density, were retrieved from the past record of patients, using the oral biopsy request forms, case notes and X-ray films (where available).

Hematoxylin and Eosin (H&E) histological glass slides and all available paraffin sections of all cases that satisfied the inclusion criteria were retrieved and re-evaluated to confirm FD diagnosis. Cases that did not satisfy the criteria were excluded from the study.

Hematoxylin and eosin (H & E) staining

H & E was routinely assessed for the lesion initially diagnosed. It served as the histological standard for the Masson's trichrome (MT) and AgNOR stained sections.

Masson's trichrome (MT) staining

MT staining was utilized in the characterization of hard tissue component of the lesions into woven bone or lamellar bone (14, 16). Red staining of lamellar bone trabeculae, and parallel and lamellate arrangement of collagen was displayed. Woven bone trabeculae stained bluish-red with osteoblasts stained bluish, with no perceptible borders between trabeculae edges and the surrounding stroma tissue. Mixed (woven and

lamellar) bone tissues were stained as patches of reddish and bluish area (17).

AgNOR staining

Black intranuclear spots were observed in cells stained positive for AgNOR.

Statistical analysis

Data was stored and analysed using IBM SPSS statistics for windows Version 20 (Armonk, NY: IBM Corp) and results were presented as simple frequencies and descriptive statistics.

Results

One hundred and thirty four cases of FD, representing 44.4% of FOLs were seen during the study period. FD was most commonly found in the age group of 10-19 years, where 69 cases (51.5%) were observed with a mean age of 18.85 ± 7.22 years (Table 1). FD was observed more frequently in females, 79 cases (58.96%) than males, 55 cases (41.04%) with a female to male ratio of 1.44: 1. FD was observed more commonly in the maxilla 99 cases (73.88%) than mandible 35 cases (26.12%). Expansion of bone was noticed in 40 (29.9%) cases. In general, ill-defined radiographic border occurred in 65% of FD. Low proportion of lamellar bone (< 30%) was observed in 28 cases (70%) of FD, (Figure 2). A relatively high proportion of mixed bone trabeculae was observed in FD (Figure 3). Mean AgNOR score of $92.3369 \pm 27.421/100$ cells ($0.9234 \pm 0.2742/\text{cell}$) was observed for FD with few intranuclei AgNOR dots in fibroblasts as shown in Figure 4. Figure 5 shows H & E staining of woven bone trabeculae.

Table 1. Distribution of fibrous dysplasia cases according to age

Age group (years)	Fibrous Dysplasia (No)	%
0-9	9	6.7
10-19	69	51.5
20-29	43	32.1
30-39	11	8.2
40-49	2	1.5
Total	134	100.0

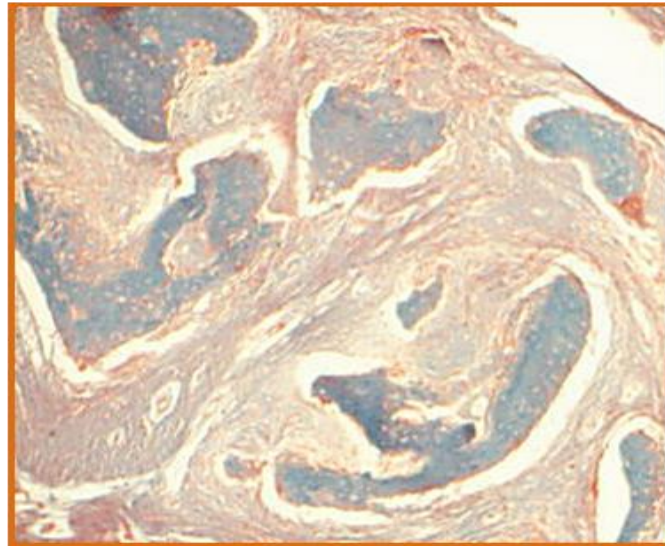


Figure 2. Histopathological image showing woven bone in a lesion of FD. Masson's trichrome staining (x100 magnification).

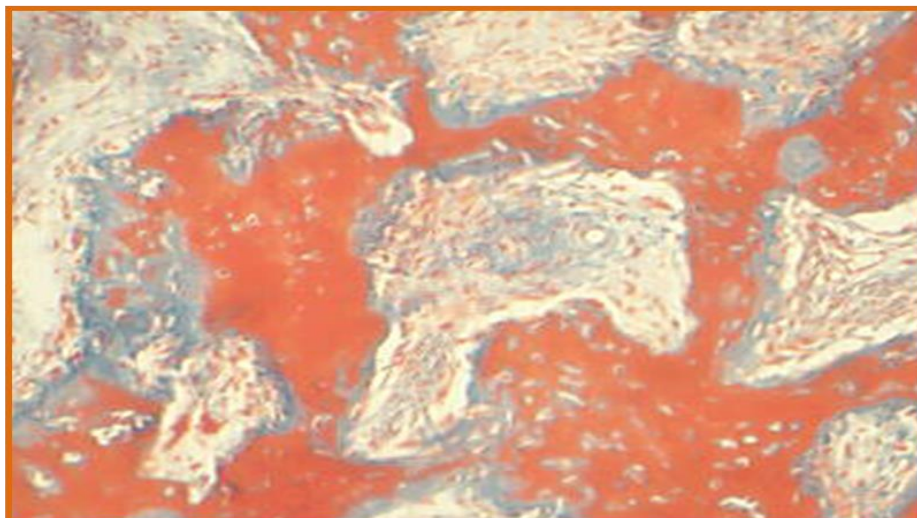


Figure 3. Histopathological image showing mixed bone trabeculae in a lesion of FD. Masson's trichrome staining (x100 magnification).

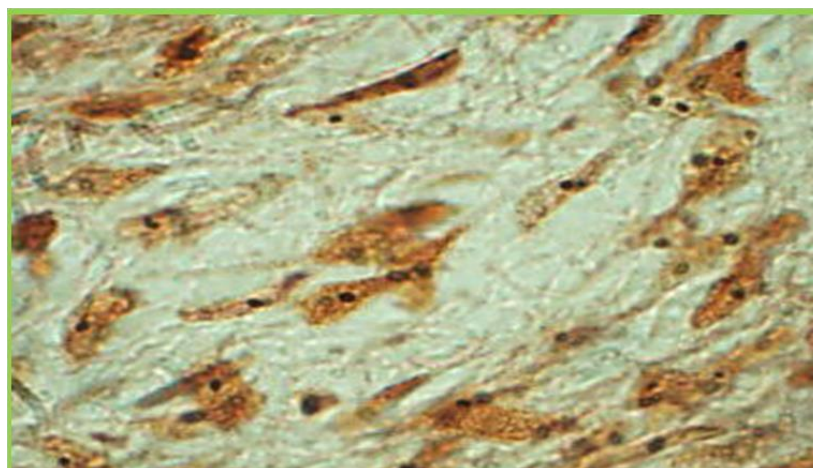


Figure 4. Immunohistochemical image showing few intranuclear black AgNOR dots in fibroblasts of FD. AgNOR staining (x1000 magnification).

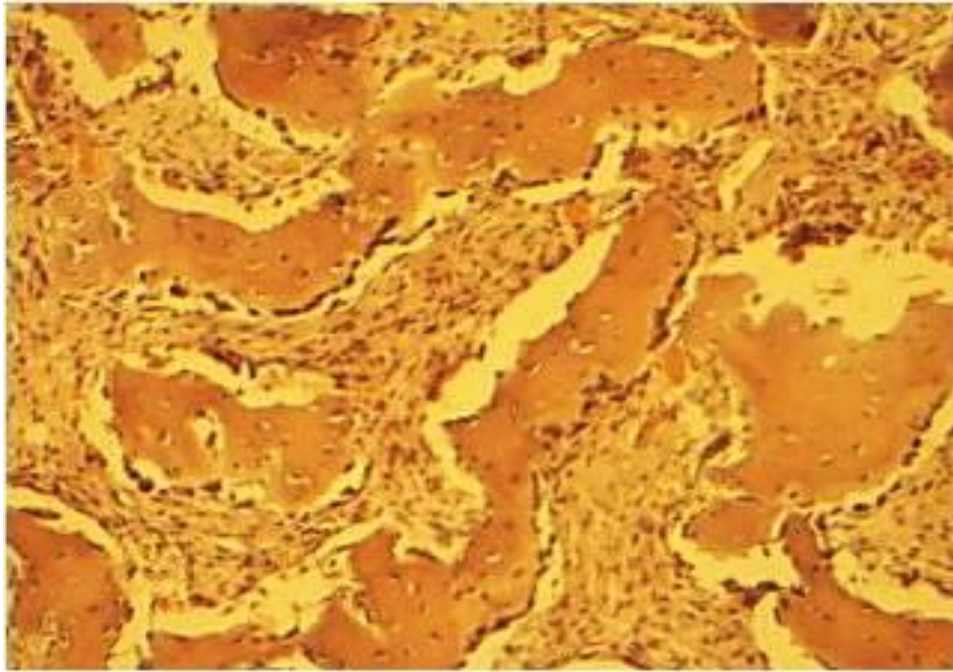


Figure 5. H & E staining of woven bone trabeculae. Woven bone trabeculae is surrounded by fibroblast-like cell in a curvilinear Chinese pattern (x40 magnification).

Discussion

In this study, the observed higher prevalence of females with a female to male ratio of 1.44:1 in FD is in agreement with previous reports in Nigeria (18-19), although 3:1 ratio have been reported by others (20-21), while MacDonasld-Jankowski reported a 1.2:1 ratio for FD (22). Furthermore, Worawongvasu and Songkampol reported 2.5:1 for FD (9). The general trend is that females were more affected than males. It could be argued that females are more conscious of their appearance than males, and therefore tend to present themselves early for treatment than the males would do.

The mean age of 18.85 ± 7.22 years observed for FD in the present study, is similar to 19.3 ± 2.3 years observed by Alsharif et al. (23), and 18.6 ± 7.2 years observed by Gulati et al. (14). Observation in this series that FD occurred at a peak age of 2nd decade agrees with reports in other studies (6, 9, 14, 22, 24-25).

FD was more common in the maxilla (73.88%) than mandible (26.12%) in this series. This observation is consistent with the report of Adekeye et al. (26). Williams et al. also reported maxillary FD

in 82.4% of their cases in Nigeria (20). It is not very clear why FD has predilection for maxilla which is a group of membrane bones. However, the findings suggest that FD can be suspected on the basis of site predilection.

The presence of relatively high proportion of mixed bone trabeculae in FD suggests that the presence of mixed bone trabeculae could be a more important histological criterion in identifying FD than the presence of pure woven bone, and that it should also be an important criterion to distinguish FD from ossifying fibroma (OF). It could be argued that the presence of high proportion of mixed bone trabeculae associated with FD (Figure 2) in the present study may be attributed to slow turnover of the bone from pure woven to pure lamellar form as also suggested by other studies (27-28). To the best of our knowledge, the presence of mixed bone trabeculae as a histological parameter for identifying FD and distinguishing it from OF has not been previously reported.

Zhou et al. reported ill-defined radiographic border in 84.5% of FD cases (29), and Kwon and Choi also reported such condition in 76% of FD

cases (30). These studies are consistent with our findings of 65% ill-defined borders in cases of FD. Furthermore, other studies have also documented ill-defined borders in FD (9, 22, 31).

In the present study a mean AgNOR score of 92.3369 ± 27.421 per 100 cells (0.9233/cell) was recorded for FD. This finding is consistent with mean score of 0.95/cell for FD reported in a Japanese population (33). Rare studies reported AgNOR histochemical staining application to diagnose FD of the jaws (15, 32). Nucleolar organizer regions (NORs) represent loops of DNA capable of transcribing ribosomal RNA, and thus ribosomes and protein production. They are located on the acrocentric chromosomes 13, 14, 15, 21, and 22, and are visible within the nucleolus during interphase. The NORs are associated with acidic, argyrophilic non-histonic proteins that are visualized upon silver staining. This enables their visualization as dark intranuclear dots, which can be quantified using light microscopy. AgNOR sites appear as brownish black intranuclear dots in a pale yellow background. AgNOR staining is an accurate and easily performed technique. Studies using this technique have suggested that quantitative analysis of AgNORs can be useful in estimating proliferative activity of neoplasms in surgical pathology. Eslami et al. Reported that AgNOR staining is a useful technique for differential diagnosis of osteosarcoma, OF, and FD of jaws (15).

Therefore, AgNOR technique can definitely be used as a supportive tool to routinely performed hematoxylin and eosin staining, and it also helps in prognosis and treatment management. Our study was able to establish the same range of AgNORs count as that of Eslami et al. (15) regarding FD as against OF, hence the implication for its use.

In conclusion, the present study demonstrated a female predilection, and showed that FD was most commonly observed in the 2nd decade of life. It also showed that the greater proportion of FD occurred in the maxilla. In addition, it highlighted mixed bone trabeculae pattern as a predictor of FD

using AgNOR staining.

Conflict of interest

The authors declared no conflict of interest.

References

1. Reed R J. Fibrous dysplasia of bone. A review of 25 cases. *Arch Pathol.* 1963;75:480-95.
2. Singer S R, Mupparapu M, and Rinaggio J. Clinical and radiographic features of chronic monostotic fibrous dysplasia of the mandible. *J Can Dent Assoc.* 2004;70:548-52.
3. Kumar Srichinthu K, Ragunathan Yoithaprabhunath T, Chitturi R T, et al. Fibro Osseous Lesions—Classifications, Pathophysiology and Importance of Radiology: a Short Review. *Int Biol Biomed J.* 2016;2:11-20.
4. Albright F, Butler a M, Hampton a O, et al. Syndrome characterized by osteitis fibrosa disseminata, areas of pigmentation and endocrine dysfunction, with precocious puberty in females: report of five cases. *N Engl J Med.* 1937;216:727-46.
5. Riminucci M, Robey P G, Saggio I, et al. Skeletal progenitors and the GNAS gene: fibrous dysplasia of bone read through stem cells. *J Mol Endocrinol.* 2010;45:355-64.
6. Neville B W, Damm D D, Chi a C, et al., Oral and maxillofacial pathology. 2015: Elsevier Health Sciences.
7. White S and Pharoah M. Benign tumors of the jaws. *Oral radiology: Principles and interpretation.* 2004;5:424-8.
8. Dorfman H D. New knowledge of fibro-osseous lesions of bone. *Int J Surg Pathol.* 2010;18:62S-5S.
9. Worawongvasu R and Songkarnpol K. Fibro-osseous lesions of the jaws: an analysis of 122 cases in Thailand. *J Oral Pathol Med.* 2010;39:703-8.
10. Alawi F. Benign fibro-osseous diseases of the maxillofacial bones: a review and differential diagnosis. *Am J Clin Pathol.* 2002;118:S50-S70.
11. Eversole R, Su L, and Elmofty S. Benign fibro-osseous lesions of the craniofacial complex a review. *Head Neck Pathol.* 2008;2:177-202.
12. Akintoye S O, Lee J S, Feimster T, et al. Dental characteristics of fibrous dysplasia and McCune-Albright syndrome. *Oral Surg Oral Med Oral Pathol Oral Radiol Endod.* 2003;96:275-82.
13. Liu Y, Wang H, You M, et al. Ossifying fibromas of the jaw bone: 20 cases. *Dentomaxillofac Radiol.* 2010;39:57-63.
14. Gulati A, Rao N, and Radhakrishnan R A. Fibrous dysplasia and ossifying fibroma—an advent in their diagnosis. *J Clin Exp*

Dent. 2011;3:e297-302.

15. Eslami M and Alaeddini F B M. Diagnostic value of silver-stained nucleolar Organizer regions in osteosarcoma, fibrous Dysplasia and ossifying fibroma of the jaws. Acta Medica Iranica. 2005;43:243-8.
16. Yoon J H, Kim J, Lee C K, et al. Clinical and Histopathological Study of Fibro-osseous. onsei Med J. 1989;30:133-43.
17. Baker F J and Silverton R E. Introduction to medical laboratory technology. 2001;Bounty Ibadan:225-33.
18. Odeku E, Martinson F, and Akinosi J. Craniofacial fibrous dysplasia in Nigerian Africans. Plast Reconstr Surg. 1970;45:96.
19. Ajagbe H and Daramola J. Fibro-osseous lesions of the jaw: a review of 133 cases from Nigeria. J Natl Med Assoc. 1983;75:593.
20. Williams A, Browne R, and Akinosi J. Fibro-osseous lesions of the jaw in Nigeria. J Natl Med Assoc. 1974;66:185.
21. Abdulai A, Gyasi R, and Iddrissu M. Benign fibro-osseous lesions of the facial skeleton: an analysis of 52 cases seen at the Korle Bu Teaching Hospital. Ghana Med J. 2004;38:96-100.
22. Macdonald-Jankowski D. Fibrous dysplasia: a systematic review. Dentomaxillofac Radiol. 2009;38:196-215.
23. Alsharif M J, Sun Z-J, Chen X-M, et al. Benign fibro-osseous lesions of the jaws: a study of 127 Chinese patients and review of the literature. Int J Surg Pathol. 2009;17:122-34.
24. Ogunsalu C, Lewis A, and Doonquah L. Benign fibro-osseous lesions of the jaw bones in Jamaica: analysis of 32 cases. Oral

Dis. 2001;7:155-62.

25. Sopta J, Drazic R, Tulic G, et al. Cemento-ossifying fibroma of jaws-correlation of clinical and pathological findings. Clin Oral Investig. 2011;15:201-7.
26. Adekeye E O, Edwards M B, and Goubran G F. Fibro-osseous lesions of the skull, face and jaws in Kaduna, Nigeria. Br J Oral Surg. 1980;18:57-72.
27. Greco M A and Steiner G C. Ultrastructure of fibrous dysplasia of bone: a study of its fibrous, osseous, and cartilaginous components. Ultrastruct Pathol. 1986;10:55-66.
28. Otto F, Thomell a P, Crompton T, et al. Cbfa1, a candidate gene for cleidocranial dysplasia syndrome, is essential for osteoblast differentiation and bone development. Cell. 1997;89:765-71.
29. Zhou H J. Fibro-osseous lesions of the jaw and facial bones: a clinico-histologic-radiologic study of 138 cases. Zhonghua Kou Qiang Yi Xue Za Zhi. 1989;24:350-2, 86. Article in Chinese].
30. Kwon K Y and Choi K S. A Radiographic study of Fibro-osseous lesions of the jaw bones. J Korean Acad Oral Maxillofac Radiol. 1998;28:27-36.
31. Nityasri V, Haris P, Bose T, et al. Fibrous dysplasia a 13 year retrospective radiographic analysis in a south Indian population. Dentomaxillofac Radiol. 2011;40:282-9.
32. Nagaoka H and Okada H. A Comparative Study of the Histopathological Features and Fibroblasts Proliferative Activity between Fibrous Dysplasia and Cemento-ossifying Fibroma of the Jaw. J Oral Sci. 2000;26:347-53.