

## Fibro Osseous Lesions – Classifications, Pathophysiology and Importance of Radiology: a Short Review

Kenniyan Kumar Srichinthu<sup>1</sup>, Thukanayakanpalayam Ragunathan Yoithaprabhunath<sup>2</sup>, Ravi Teja Chitturi<sup>3\*</sup>, Andamuthu Yamunadevi<sup>4</sup>, Aparna Devi Potsangbam<sup>5</sup>  
Deepak Ningombam Singh<sup>5</sup>

1. KSR Institute of Dental Science and Research, Tamilnadu, India.
2. Vivekanandha Dental College for Women. Tamilnadu, India.
3. The University of the West Indies, St. Augustine, Trinidad and Tobago.
4. Vivekanandha Dental College for Women. Tamilnadu, India.
5. Dental college, Regional Institute of Medical Science, Imphal, India.

Submitted 20 Aug 2016; Accepted 07 Sep 2016; Published 11 Oct 2016

Fibro osseous lesions (FOLs) are a generic designation of poorly defined group of lesions which are recognized to affect the jaws and the craniofacial bones which are known for their confusing area in diagnostic pathology. The disease comprises of varied processes in which the normal architecture of bone is replaced by fibrous tissue containing varying amount of foci of mineralization. Regardless of the advancement in molecular analyzing techniques, the classification, diagnosis, and management of FOLs remain confusing due to multiple histological and radiographic similarities. Even though the histopathology for all FOLs is similar, their behavior ranges widely from dysplasia, hamartoma to benign neoplasia with occasional recurrence and hence radiology plays a central role in their diagnosis. The article throws a light on the various classification systems given for FOLs by various authors at different times due to expansion in molecular studies and also highlights the role of radiographic and other imaging techniques in the diagnosis of FOLs, which will enable us to adopt a uniform terminology and to aid the surgical pathologist in the diagnosis of this diverse group of maxillofacial lesions.

**Keywords:** Fibro osseous lesions, pathophysiology, radiography

The term fibro osseous lesions (FOLs) is a generic designation of poorly defined group of lesions affecting the jaws and cranio facial bones. They comprise a diverse group of pathologic conditions including developmental lesions, reactive or dysplastic lesions and neoplasms. All are characterized by replacement of bone by a benign connective tissue matrix. This matrix displays foci

of mineralization that vary in amount and appearance, in the form of woven bone or of cementum like round acellular intensely basophilic structures. The definitive diagnosis of FOLs is not possible only alone by examination of incisional /excisional biopsy material and it mainly relies on close clinical as well as radiological correlation. This review will throw light upon various

\*Correspondence: The University of the West Indies, St. Augustine, Trinidad and Tobago. E-mail: dr.raviteja@gmail.com

classifications, molecular pathogenic mechanisms and the importance of radiology in diagnosing the FOL (1-3).

### **Classification**

The various classifications of FOL proposed by different authors are listed below.

- 1985 - Charles Waldron
- 1987 - Working classification by Mico M. Malek
- 1990 - Peiter J. Slootweg & Hellmuth Muller
- 1992 - World health organization (WHO) classification
- 1993 - Modified classification by Waldron
- 2001 - Brannon & Fowler classification
- 2005 - WHO classification of FOL
- 2006 - Paul M. Speight & Roman Carlos classification
- 2008 - Eversole classification

### **Charles Waldron classification of FOLs, 1985 (4)**

#### **1. Fibrous dysplasia (FD)**

- a. Monostotic
- b. Polyostotic

#### **2. Fibro-osseous (cemental) lesions presumably arising in the periodontal ligament**

- a. Periapical cemental dysplasia
- b. Localized fibro-osseous-cemental lesions (probably reactive in nature)
- c. Florid cemento-osseous dysplasia (gigantiform cementoma)
- d. Ossifying and cementifying fibroma

#### **3. Fibro-osseous neoplasms of uncertain or detectable relationship to those arising in the periodontal ligament**

- a. Cementoblastoma, osteoblastoma & osteoid osteoma
- b. Juvenile active ossifying fibroma & other so called aggressive ossifying / cementifying fibromas.

### **Working classification of fibro-osseous**

### **lesions by Mico M. Malek, 1987 (5)**

In 1987 based on the viewpoint of diagnostic pathologist, a working classification of fibro-osseous lesions was given by Mico M. Malek which is as follows

1. Developmental disorders
  - a. Fibrous cortical defects (non ossifying fibroma)
  - b. Fibrous dysplasia
2. Reactive reparative lesions
  - a. Traumatic periosteitis
  - b. Periosteitis ossificans
  - c. Osseous keloid
  - d. Periapical cemental dysplasia & florid cemento-osseous dysplasia
  - e. Sclerosing osteomyelitis (focal & diffuse type)
  - f. Osteitis deformans
3. Fibromatosis
  - a. Desmoplastic fibroma (intraosseous fibromatosis)
4. Neoplasms
  - a. Tooth bearing areas only
    - i. Cementoblastoma
    - ii. Periodontoma
  1. Central
  2. Peripheral
    - b. All cranio-facial bones (Including tooth bearing areas)
      - i. Osteoma
  1. Trabecular
  2. Compact
    - ii. Osteoid osteoma
    - iii. Psammous desmo-osteoblastoma
    - iv. Trabecular desmo-osteoblastoma

### **Peiter J. Slootweg & Hellmuth Muller, 1990 (6)**

In 1990 Peiter. J. Slootweg & Hellmuth Muller gave a classification which emphasis primarily on the histopathological features, and they underscored that this classification requires inclusion of adjacent normal bone to make diagnosis.

Group I: Fibrous dysplasia (FD)

Group II: Juvenile ossifying fibroma (JOF)

Group III: Ossifying fibroma (OF)

Group IV: Periapical cemental dysplasia and florid osseous dysplasia

### **WHO classification, 1992 (7)**

In the second edition of the WHO classification in 1992, the cemental lesions were included in the “neoplasm and other tumors related to bone group” leaving behind cementoblastoma, a true neoplasm of dental cemental structure. In the same year, the second edition of the “WHO histological classification of odontogenic tumors” recognized these cemental lesions as the group of cemento-osseous dysplasias, encompassing florid cement-osseous dysplasia which occurs with periapical cemental dysplasia and other cemento-osseous dysplasia.

1. Osteogenic neoplasms
  - a. Cemento-ossifying fibroma
2. Non-neoplastic bone lesions
  - a. Fibrous dysplasia of jaws
  - b. Cemento-osseous dysplasia (COD)
    - i. Periapical cemental dysplasia
    - ii. Florid cemento-osseous dysplasia (gigantiform and familial multiple cementoma)
    - iii. Other cemento-osseous dysplasia
  - c. Cherubism (familial multilocular cystic disease of the jaws)
  - d. Central giant cell granuloma
  - e. Aneurysmal bone cyst
  - f. Solitary bone cyst

### **Modified Classification by Waldron, 1993 (8)**

In 1993, Waldron had reviewed the subject of benign fibro-osseous lesions (BFOL) of jaws, and suggested a modification of his earlier classification to overcome the demerits of his own classification.

1. Fibrous dysplasia

2. Cemento-osseous dysplasia
  - a. Periapical cemento-osseous dysplasia
  - b. Focal cemento-osseous dysplasia
  - c. Florid cemento-osseous dysplasia
3. Fibro-osseous neoplasm
  - a. Cementifying /ossifying / cemento-ossifying fibroma.

### **Brannon & Fowler classification, 2001 (3)**

Brannon & Fowler in 2001 had formulated a classification, by including more number of lesions showing the similarity of FOL which stood differed from that of Waldron & WHO classifications.

1. Osseous dysplasia (OD) (reactive)
  - a. Non-hereditary
    - i. Periapical
    - ii. Focal
    - iii. Florid
  - b. Hereditary (developmental)
    - i. Familial gigantiform cementoma
2. Fibro-osseous neoplasm
  - a. Ossifying fibroma (OF)
  - b. “Juvenile”, “Active” or “Aggressive” variants of OF
3. Fibrous dysplasia
  - a. Polyostotic FD
  - b. Monostotic FD
  - c. Craniofacial FD
4. Giant cell lesions
  - a. Central giant cell granuloma
  - b. Aneurysmal bone cyst
  - c. Cherubism
5. Miscellaneous benign fibro-osseous lesions
  - a. Cementoblastoma
  - b. Tori/exostoses
  - c. Osteoma

### **WHO Classification of FOLs, 2005 (7)**

In the latest WHO classification of odontogenic tumors in 2005, the cemento osseous dysplasia have been called osseous dysplasia. The

core of this classification is the concept of a spectrum of clinicopathological entities in which the diagnosis can only be made by the correlation of clinical, radiological as well as by histological features.

1. Ossifying fibroma (OF)
2. Fibrous dysplasia
3. Osseous dysplasia
  - a. Periapical osseous dysplasia
  - b. Focal osseous dysplasia
  - c. Florid osseous dysplasia
  - d. Familial gigantiform cementoma
4. Central giant cell granuloma
5. Cherubism
6. Aneurysmal bone cyst
7. Solitary bone cyst

### **Paul M. Speight & Roman Carlos classification, 2006 (2)**

Paul M. Speight & Roman Carlos in 2006 gave a classification based on all the previous classifications, concentrating mainly on the histopathological features to guide the surgical pathologist towards a definitive diagnosis.

1. Fibrous dysplasia
  - a. Monostotic FD
  - b. Polyostotic FD
  - c. Craniofacial FD
2. Osseous dysplasia
  - a. Periapical osseous dysplasia
  - b. Focal osseous dysplasia
  - c. Florid osseous dysplasia
  - d. Familial gigantiform cementoma
3. Ossifying fibroma
  - a. Conventional ossifying fibroma
  - b. Juvenile trabecular ossifying fibroma
  - c. Juvenile psammomatoid ossifying fibroma

### **Eversole classification, 2008 (9)**

In 2008, Eversole et al. gave a comprehensive classification by including developmental lesions, neoplastic lesions and inflammatory

/reactive processes. This classification emphasized that final diagnosis can be attained by correlation of microscopic, imaging and clinical features together but not on the basis of histopathological features alone.

1. Bone dysplasias
  - a. Fibrous dysplasia
    - i. Monostotic
    - ii. Polyostotic
    - iii. Polyostotic with endocrinopathy (McCune-Albright)
    - iv Osteofibrous dysplasia
  - b. Osteitis deformans or Pagets disease
  - c. Pagetoid heritable bone dysplasias of childhood
  - d. Segmental odontomaxillary dysplasia
2. Cemento-osseous dysplasias
  - a. Focal cemento-osseous dysplasia
  - b. Florid cemento-osseous dysplasia
3. Inflammatory/reactive processes
  - a. Focal sclerosing osteomyelitis
  - b. Diffuse sclerosing osteomyelitis
  - c. Proliferative periostitis
4. Metabolic Disease: hyperparathyroidism
5. Neoplastic lesions (ossifying fibromas)
  - a. Ossifying fibroma
  - b. Hyperparathyroidism jaw lesion syndrome
  - c. Juvenile ossifying fibroma
    - i. Trabecular type
    - ii. Psammomatoid type
  - d. Gigantiform cementomas

### **Pathophysiology of FOLs Fibrous dysplasia**

Fibrous dysplasia (FD) is a benign dysplastic disease with a well-known genetic basis (10, 11). FD is a condition that results from a mutation in (Guanine nucleotide binding protein alpha stimulating activity polypeptide 1 (*GNAS 1*) gene. The clinical severity of the condition depends upon the time of *GNAS 1* mutation occurrence during fetal or postnatal life. If mutation occurs during the early

embryonic life, the osteoblast, melanocyte and endocrine cells carry the mutation and express the mutated gene in form of multiple bone lesions, cutaneous pigmentation and endocrine disturbances (McCune Albright syndrome). If mutation occurs in later stages of embryonic stage, the progenies of mutated cell will disperse and participate in the formation of skeleton resulting in multiple bone lesions (polyostotic FD). If mutation occurs during the postnatal life, the progenies of mutated cell are confined to one site resulting in FD affecting a single bone (monostotic FD) (12).

Mutations in the alpha subunit of a G stimulatory protein lead to constitutive activation of adenylyl cyclase, resulting in a persistent elevation of cyclic adenosine monophosphate (cAMP) and stimulation of endocrine receptors. The increase in cAMP as a result of the genetic mutation has several so-called downstream effects (13). The constitutive elevation in cAMP level caused by G $\alpha$  mutations results in abnormal expression of several target

genes such as c-fos, c-jun, interleukin-6 (IL-6) which contain cAMP-responsive elements in their promoter which in turn affects the transcription and expression of several downstream genes and therefore leads to osteoblast recruitment and function disturbance in dysplastic bone lesions (14-16). (Increased number of osteoclasts and bone resorption observed in fibrous dysplasia<sup>(</sup> have been attributed to (IL-6) (Figure 1).

In a study accomplished by Candelieri et al., (14) bone marrow spaces of FD-affected bones were shown to contain high levels of c-fos, while healthy subjects bones or uninvolved bones of FD patients showed no c-fos expression. Intracellular cAMP raises in bone marrow osteoprogenitor cells of FD-affected bones, leading to cell proliferation together with differentiation defects.

The bone expansion, which is the important clinical manifestation of this disease, can be explained by cellular proliferation and the pathological finding of immature woven bone

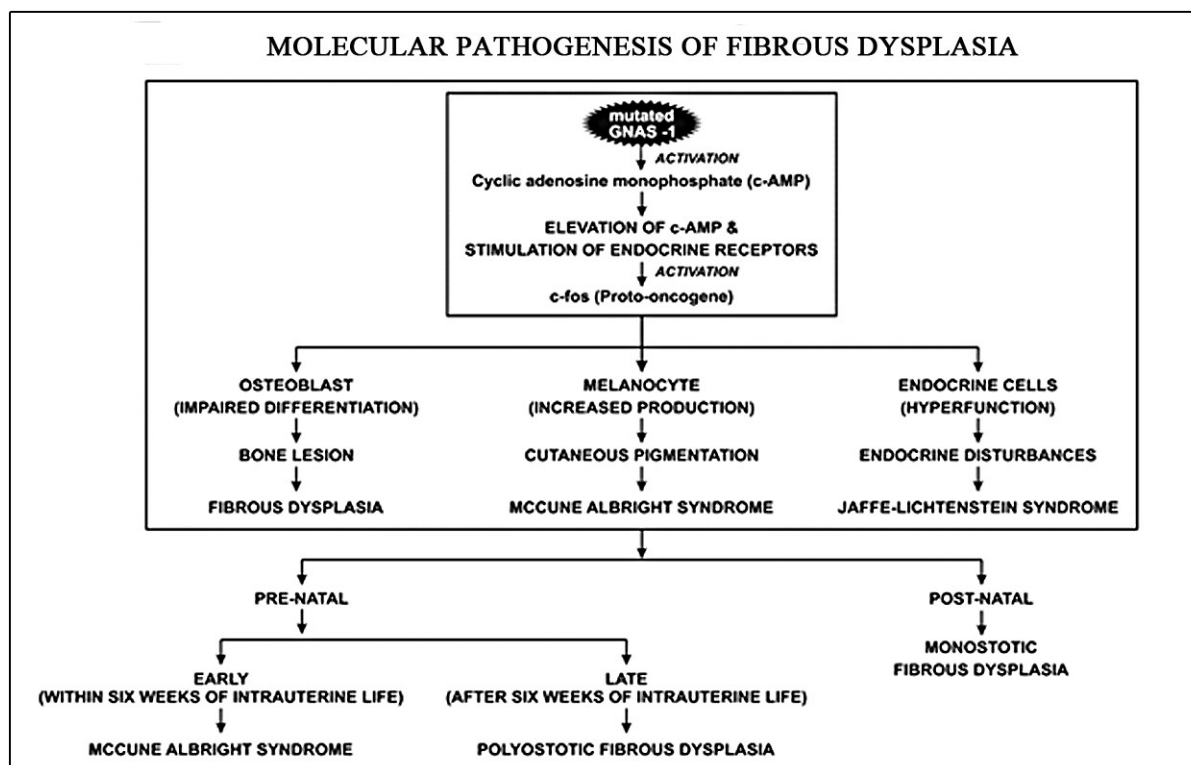


Figure 1. Flowchart representing the molecular pathogenesis of fibrous dysplasia.

manifests the inappropriate differentiation which is caused by the mutated gene.

### Pagets disease

Osteitis deformans or Paget disease of bone (PDB) is an osseous dysplasia that is characterized by rapid bone turnover and remodeling throughout the skeleton. The cause of PDB is not completely understood, but the two main theories of causative agents are viral (Paramyxoviral infection) and genetic. Sequestosome 1 (*SQSTM1*), tumor necrosis factor receptor superfamily member -11A (*TNFRSF11A*), and valosin containing protein (*VCP*), are among genes responsible for disease development (12-17).

Patients affected with PDB show nuclear or cytoplasmic inclusions with high resemblance to paramyxovirus nucleocapsids in their cells, suggesting the implication of viral factors in disease development (18, 19). Furthermore, *in vitro* experiments have shown that bone marrow cultures infected with paramyxovirus, or expressing viral nucleocapsid protein, can induce the formation of osteoclast-like cells with pagetic characteristics (20-22). The diseases involve defective function of the osteoprotegerin (*OPG/TNFRSF11B*) / Receptor activator of nuclear factor kappa-B ligand (*RANKL/TNFRSF11A/B*) / Receptor Activator of Nuclear Factor  $\kappa$  B (*RANK*) pathway, a molecular regulator of osteoclastogenesis. The classic form of PDB is often associated with inactivation mutations in the *OPG* gene. Mutations in *SQSTM1* which encodes a protein called p62, is involved in regulating the function of osteoclasts (23). The mutated protein fails to suppress the osteoclastic resorption. In Paget's disease with inclusion body myopathy and fronto temporal dementia, mutation in the *VCP* (valosin – containing protein) which interacts with the inhibitor of NFkappaB for proteosomal degradation are identified.

### Osseous dysplasia

Osseous dysplasia is the most common form of FOL in the jaw bones (24). Osseous dysplasia develop only in tooth-bearing regions, it is hypothesized that elements present in the periodontal ligament space or teeth and periodontium present in the jaw bones are at the origin of this unique group of lesions (24-26). (These lesions have distinct predilection for females, probably due to hormonal imbalance which influences bone remodeling process (27).

### Ossifying fibroma

Ossifying fibromas are considered as benign fibro-osseous neoplasms which are principally encountered within the jawbones (3, 12, 24). Although the cell of origin for OFs is unknown, the OFs may derive from elements present in the periodontal ligament space (26, 28). Sawyer JR et al found a balanced translocation with recurring breakpoints at Xq26 and 2q33 in patients affected with OF (29).

Dal Cin et al. also reported a mandibular OF with an interstitial deletion on chromosome 2 between q31-32 and q35-36 (30). Very few molecular studies have identified mutations in *CDC73* (cell division cycle 73) / *HRPT2* a gene that encodes parafibromin protein (9).

### Inflammatory / reactive process and metabolic bone disease

Most infections of the jaws are odontogenic in origin. Pyogenic and anaerobic bacteria are usually responsible for acute, sub-acute and/ or chronic osteomyelitis.

*CDC73/HRPT2*, a tumor suppressor gene is found to be mutated in hyperthyroidism– jaw tumor syndrome which includes familial parathyroid adenomas, OF, renal cyst, and willms tumor (9).

### The importance of radiology in the diagnosis of FOLs

Maxillofacial FOLs are of particular interest

Table 1. Genetic alterations in fibro osseous lesions (9)

Disease	Genomic alterations
Fibrous dysplasia	<i>GNAS-1</i>
Adult PD	<i>SQSTM-1</i>
Childhood PD	<i>TNFRSF11A</i>
Hereditary syndrome with inclusion body, myopathy and frontotemporal dementia.	<i>VCP</i>
Hyperthyroidism associated with ossifying fibroma.	<i>HRPT2</i>
Ossifying fibroma	<i>HRPT2</i>
Psammomatoid ossifying fibroma	t (X;2)

to radiologists because they emphasize the prime role in diagnosing the lesion. This role arises because the pathology for all FOLs is identical, though they range widely in behavior, from dysplasia, hamartoma to neoplasia. Radiological assessment of the anatomical location of a bone tumor, its shape, size, its margins, the pattern of matrix and its destruction, and the soft tissue abnormalities generally correlate with its behavior (aggressive or benign) (31). Rad-iologic methods include panoramic and plain films.

Many FOLs, (particularly COD) are symptomless and require no surgical treatment (24). Therefore, diagnosis of the lesions on clinical and radiological features alone may obviate the need for an otherwise unnecessary invasive procedure. In patients with BFOLs, especially of the maxillofacial bones, radiographs are essential to sub-classify and to diagnose a given lesion (32, 33). Due to the presence of overlapping histopathological characteristics of lesions, microscopic analyzes are not sufficient for adequate diagnosis of FOLs. Satisfactory clinical and para clinical data, such as patient’s age, sex, location of the lesion, duration of symptoms, imaging character-istics, and histologic findings are necessary to achieve an accurate diagnosis (34).

The radiographic appearance of most of the FO lesions varies with the stage of development and amount of bony matrix within the lesion. On a plain or panoramic film, early lesions appear radiolucent, while later lesions may appear sclerotic (32).

**Advanced imaging techniques:**

Advanced imaging techniques such as computed tomography (CT), magnetic resonance imaging (MRI), ultra sound (US) and whole-body bone scintigraphy can also have a complementary role in definitive diagnosis (35, 36).

**Computed tomography**

CT scanning is the best technique for demonstrating the radiographic characteristics of FD. The presentation of superior bony detail and exact assessment of the extent of the lesion, make this method preferable to radiographs or magnetic resonance imaging for diagnosis and follow-up of FD (13, 32).

CT can show intracortical osteolysis with characteristic sclerotic band (osteoblastic rimming) and moderate cortical expansion in OF.

**Magnetic Resonance Imaging**

MRI is a sensitive mean of establishing the lesion’s shape, content and size. When MRI is performed in conjunction with CT imaging it provides

Table 2. Radiological features of fibro osseous lesion (9)

Disease	Radiographic lesions
Fibrous dysplasia	<ul style="list-style-type: none"> <li>• Ground glass or orange-peel appearance.</li> <li>• Poorly discernible borders that blend with the surrounding, unaffected bone.</li> </ul>
Osteitis deformans	<ul style="list-style-type: none"> <li>• Cotton wool appearance</li> <li>• Teeth in the affected regions usually demonstrate hypercementosis.</li> </ul>
Ossifying fibroma	<ul style="list-style-type: none"> <li>• Well circumscribed, unilocular sharply defined smooth corticated border</li> <li>• Downward bowing of the inferior cortex of mandible</li> </ul>
Osseous dysplasia	<i>i. Periapical</i> Multiple, circumscribed, noncorticated radiolucencies.
	<i>ii. Focal</i> Focal circumscribed apical lesions $\leq 2$ cm.
	<i>iii. Florid</i> Multi quadrant opacities
Focal sclerosing osteomyelitis	Apical well delineated lucent, target or opaque
Diffuse sclerosing osteomyelitis	Diffuse ground glass proliferative periostitis
Hyperparathyroidism	<ul style="list-style-type: none"> <li>• Multilocular radiolucency</li> <li>• Loss of lamina dura around the tooth</li> </ul>

useful data.

Signal intensity on T1- and T2-weighted images and the degree of contrast enhancement on T1-weighted images depend on the amount and degree of fibrous tissue, bone trabeculae, cellularity, collagen, cystic and hemorrhagic changes. Because the lesion is composed mainly of fibrous tissue and osteoid with a low water content, T1-weighted images have a low-intensity signal while T2-weighted images have a higher-intensity signal (13, 32).

In OF, MRI reported signal characteristics show, low density signal in T1-weighted image and iso-high signal in T2-weighted image.

### Bone scintigraphy

Bone scintigraphy is a sensitive imaging modality that is useful for detecting early FD, as well as for determining the extent of polyostotic disease (36).

In PD, bone scintigraphy is highly sensitive but not specific. There is a marked increased uptake in all phases of disease (37).

### Conclusion

FOLs of the maxillofacial bones make up a diverse collection of disorders that include neoplastic and non-neoplastic and hereditary and non-hereditary conditions. FOLs of the jaw have been under frequent renaming and reclassification due to their varied features. FOLs share many histopathological features like the replacement of the normal bone with fibrous connective tissue which is sometime interspersed with mineralized products such as osteoid, psammoma body mature bone or cementum like calcifications. A wide knowledge on the molecular biology behind this group of lesions is essential to understand the differing radiological pattern exhibited by them. Hence, the definitive diagnosis of FOLs requires correlation with the clinical and radiological findings. Sometimes advanced imaging may pave the way to accurate diagnosis.

### Conflict of interest

The authors declared no conflict of interest.



## References

1. Alawi F. Benign fibro-osseous diseases of the maxillofacial bones. A review and differential diagnosis. *Am J Clin Pathol* . 2002;118:S50-70.
2. Speight P M, Carlos R. Maxillofacial fibro-osseous lesions. *Curr Diagn Pathol*. 2006;12:1-10.
3. Brannon R B, Fowler C B. Benign fibro-osseous lesions: a review of current concepts. *Adv Anat Pathol*. 2001;8:126-43.
4. Waldron C A. Fibro-osseous lesions of the jaws. *J Oral Maxillofac Surg*. 1985;43:249-62.
5. Makek M S. So called “fibro-osseous lesions” of tumorous origin: biology confronts terminology. *J Craniomaxillofac Surg*. 1987;15:154-67.
6. Slootweg P J, Müller H. Differential diagnosis of fibro-osseous jaw lesions: a histological investigation on 30 cases. *J Craniomaxillofac Surg*. 1990;18:210-4.
7. Barnes L, Eveson JW, Reichart P, et al. World Health Organisation classification of tumours: pathology and genetics of head and neck tumours. IARC Press, Lyon; 2005
8. Akcam T, Altug H A, Karakoc O, et al. Synchronous ossifying fibromas of the jaws: a review. *Oral Surg Oral Med Oral Pathol Oral Radiol*. 2012 Nov;114:S120-5.
9. Eversole R, Su L, ElMofty S. Benign fibro-osseous lesions of the craniofacial complex a review. *Head Neck Pathol*. 2008;2:177-202.
10. MacDonald-Jankowski D. Fibro-osseous lesions of the face and jaws. *Clin Radiol*. 2004;59:11-25.
11. Dorfman H D. New knowledge of fibro-osseous lesions of bone. *Int J Surg Pathol*. 2010;18:62-5.
12. Neville BW, Damm DD, Allen CM, et al. Bone pathology. In: Neville BW, Damm DD, Allen CM, et al, eds. *Oral and Maxillofacial Pathology*. 2nd ed. Philadelphia, PA: Saunders; 2002: 542-578.
13. DiCaprio M R, Enneking W F. Fibrous dysplasia. *J Bone Joint Surg Am*. 2005;87:1848-64.
14. Candelieri G A, Glorieux F H, Prud'homme J, et al. Increased expression of the c-fos proto-oncogene in bone from patients with fibrous dysplasia. *N Engl J Med*. 1995;332:1546-51.
15. Marie P J. Cellular and molecular basis of fibrous dysplasia. *Histol Histopathol*. 2001;16:981-8.
16. Toyosawa S, Yuki M, Kishino M, et al. Ossifying fibroma vs fibrous dysplasia of the jaw: molecular and immunological characterization. *Mod Pathol*. 2007;20:389-96.
17. Monfort J, Sala D R e, Romero A, et al. Epidemiological, clinical, biochemical, and imaging characteristics of monostotic and polyostotic Paget's disease. *Bone*. 1999;24:13S-14S.
18. Rebel A, Malkani K, Basle M, et al. Ultrastructural characteristics of osteoclasts in Paget's disease. *Rev Rhum Mal Osteoartic*. 1974;41:767-71.
19. Mills B G, Singer F R. Nuclear inclusions in Paget's disease of bone. *Science*. 1976;194:201-2.
20. Mee A, May C, Bennett D, et al. Generation of multinucleated osteoclast-like cells from canine bone marrow: effects of canine distemper virus. *Bone*. 1995;17:47-55.
21. Reddy S V, Kurihara N, Menea C, et al. Osteoclasts Formed by Measles Virus-Infected Osteoclast Precursors from hCD46 Transgenic Mice Express Characteristics of Pagetic Osteoclasts 1. *Endocrinology*. 2001;142:2898-905.
22. Kurihara N, Reddy S V, Menea C, et al. Osteoclasts expressing the measles virus nucleocapsid gene display a pagetic phenotype. *J Clin Invest*. 2000;105:607-14.
23. Ralston S H. Paget's disease of bone. *N Engl J Med*. 2013;368:644-50.
24. Waldron C A. Fibro-osseous lesions of the jaws. *J Oral Maxillofac Surg*. 1993;51:828-35.
25. Eisenberg E, Eisenbud L. Benign Fibro-Osseous

- Disease: Current Concepts in Historical Perspective. *Oral Maxillofac Surg Clin North Am.* 1997;9:551-62.
26. Melrose R. The clinico-pathologic spectrum of cemento-osseous dysplasia. *Oral Maxillofac Surg Clin North Am.* 1997;9:643-54.
27. Kramer IR, Pindborg JJ, Shear M. *Histological Typing of Odontogenic Tumors.* 2nd ed. Berlin, Germany: Springer-Verlag 1992; 83: 28-31.
28. Eversole L, Leider A, Nelson K. Ossifying fibroma: a clinicopathologic study of sixty-four cases. *Oral Surg Oral Med Oral Pathol.* 1985;60:505-11.
29. Sawyer J R, Tryka A F, Bell J M, et al. Nonrandom chromosome breakpoints at Xq26 and 2q33 characterize cemento-ossifying fibromas of the orbit. *Cancer.* 1995;76:1853-9.
30. Dal Cin P, Sciot R, Fossion E, et al. Chromosome abnormalities in cementifying fibroma. *Cancer Genet Cytogenet.* 1993;71:170-2.
31. Kilpatrick S, Ward Sr W. The pathologist's role in the diagnosis of bone tumors: informed versus uninformed. *Instr Course Lect.* 1999;48:613.
32. Mohammadi-Araghi H, Haery C. Fibro-osseous lesions of craniofacial bones. The role of imaging. *Radiol Clin North Am.* 1993;31:121-34.
33. Mayer D, Siskind B, Caputo Rosen D. Imaging and interpretation of fibro-osseous disease. *Oral Maxillofac Surg Clin North Am.* 1997;9:607-24.
34. Chauhan I, Roy S, Garg V, et al. Fibro-osseous lesions of the jaws: An insight. *Int J Contemp Dent Med Rev.* 2015;2015.
35. Yongjing G, Huawei L, Zilai P, et al. McCune-Albright syndrome: radiological and MR findings. *JBR-BTR.* 2001;84:250-2.
36. JOHNS W D, GUPTA S M, KAYANI N. Scintigraphic evaluation of polyostotic fibrous dysplasia. *Clin Nucl Med.* 1987;12:627-31.
37. Smith S E, Murphey M D, Motamedi K, et al. From the Archives of the AFIP: Radiologic Spectrum of Paget Disease of Bone and Its Complications with Pathologic Correlation 1. *Radiographics.* 2002;22:1191-216.