

# The First Reported Case of Breast Granulomas Secondary to Huge Amount of Baby Oil Self-injection

Aybala Agac<sup>1\*</sup>, Saadet Akturan<sup>1</sup>, Tuba Hilal Guclu<sup>2</sup>, Ahmet Alyanak<sup>1</sup>, Huseyin Gobut<sup>1</sup>,  
Gulten Kiyak<sup>1</sup>

1. Yildirim Beyazıt University Yenimahalle Training and Research Hospital, General Surgery, Ankara, Turkey.

2. Yildirim Beyazıt University Yenimahalle Training and Research Hospital, Aesthetic and Plastic Surgery, Ankara, Turkey.

Submitted 16 Nov 2016; Accepted 26 Dec 2016; Published 14 Jan 2017

Using fillers for aesthetic corrections purposes are becoming more and more popular amongst patients due to its less invasive nature compared to surgery. A 46-year old female patient said after her first baby born, she lost the perkiness and fullness of the breasts. Then she injected her breasts with baby oil found at home with a syringe with about 200 cc for each breast and she was quite content with the results. Segmented mastectomy and reconstruction was performed. The post-op pathology results reported the removed tissue as foreign-body granulation tissue. This is the first report of breast baby oil self-injection complications in the literature.

**Keywords:** Breast fillers, self-injection, foreign body granuloma

Using fillers for aesthetic corrections purposes are becoming more and more popular amongst patients due to its less invasive nature compared to surgery. In the case presented below, we discuss medical and non-medical filler procedures and their complications based on previously published studies in the literature.

## Case presentation

A 46-year old female patient was directed from an outside clinic to ours with a pre-diagnosis of breast cancer for advanced diagnosis and treatment. Mammography revealed bilateral breast cancer suspicion in the patient (Figure 1). In physical examination, inspection of the breasts revealed severe mobility impairment in both breasts. While

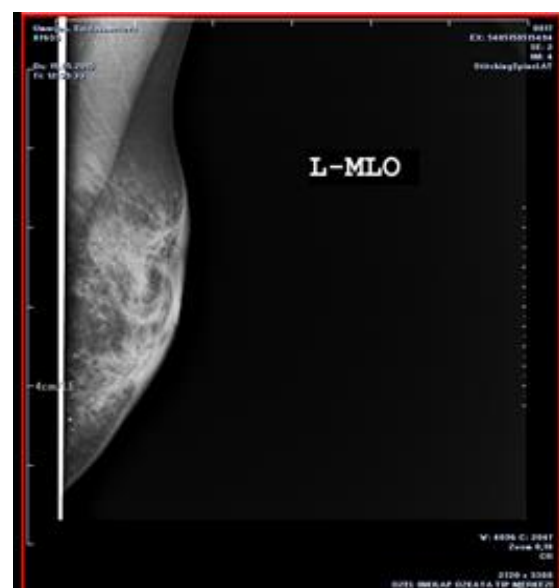


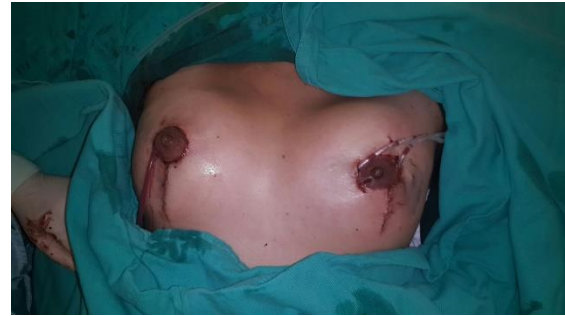Figure 1. Mammogram of left breast of the patient.

\*Correspondence: Yildirim Beyazıt Üniversitesi Yenimahalle Eğitim ve Araştırma Hastanesi, Yenimahalle, Ankara, Turkey.  
E-mail: draybala.a@gmail.com

outer quadrant of right breast was mobile in arm raises and bending over moves, inner quadrant was fixated on pectoralis muscle. Left breast was completely fixated on pectoralis muscle and did not show any mobility in any of these movements (Figure 2). When palpated, left breast was completely rock-solid and in right breast, multifocal solid masses starting from 7 cm in diameter were detected in inner quadrant. Multiple biopsies were done on both breasts using true-cut. Pathology results showed sclerosing adenosis, insufficient material and foreign body granulation tissue. While prepping the patient for open surgical biopsy, the patient was again interviewed in detail and the possible diagnoses and their severity were explained. The patient then said that she had her first birth while she was 18, that she lost the perkiness and fullness of the breasts following birth. Then she injected her breasts with baby oil found at home with a syringe with about 200 cc for each breast and she was quite content with the results. She had 2 more births following that, and she was able to breastfeed her babies for about 1 year following birth without any problems. She recently started having pain while sleeping on her stomach and while lifting heavy things due to her breasts becoming more solid and that was the main complaint she had. Following a consultation from plastic surgery, segmented mastectomy with multiple segments was performed on the patient. The defect was reconstructed with silicone prosthetics (Figure 3). Post-op pathology results reported the removed tissue as foreign-body granulation tissue. The patient is currently on



**Figure 2.** Panaromic view of both breasts prior to surgery.



**Figure 3.** Surgical excision and reconstruction with implants of both breast.

follow-up and fat injections are planned for the minimal retractions on breast skin.

## Discussion

Synthetic injectable fillers have a wide usage for surgical skin rejuvenations (1). There are also more long-term fillers which are known to carry a higher complication risk when compared with short-term fillers (1-2). Long-term fillers cause these effects due to the body's host versus foreign-body response against the micro particles found within the filler materials. This host response increases the lifespan of the filler material and minimizes the migration risk (2-3).

As with every material, the misuse of these materials are quite possible. In this presented case, there was a 200 cc of baby oil self-injection in a household environment to each breast, which is a huge amount. This is thought to be a first in the literature. A similar study published by Wilson et al. in 2014 reported that using illegal or unlicensed filler materials amongst transgender individuals are very common in San Francisco, USA (4). The main difference in the present study is that while our study deals with a self-injection by the individual, the transgender individuals have these procedures done illegally either by amateurs or unlicensed practitioners without proper education or authorization to perform such procedures. This is thought to be due to economic and confidentiality reasons. Wilson et al.'s study classified the possible side-

effects from mild to mortal and reported the side effects from blood clot formation to multiple organ failure and death; listed by their frequency (4).

The diagnosis in those patients are usually done in clinical settings (5). For imaging studies, ultrasonography or MRI can be used. Likewise, mammography results falsely reported multifocal breast tumor in our case. In the situations when breast biopsies are indicated for a definite diagnosis, giant-cell foreign body reactions are characteristically seen on the biopsy results (5).

Treatment planning should be done on a case-by-case basis (6). In the present case, we considered total excision and reconstruction at the same session due to the volume of the lesions.

To sum up, misuse of fillers are exceptional situations with possibly very severe complications and they require special and urgent treatment. In addition, as in the present case, detailing of the patient history with even a bit of pressure might be beneficial in obtaining the maximum advantage in patient diagnosis and treatment.

### Conflict of interest

The authors declared no conflict of interest.

### References

1. Onranifard M, Taheri S. Filler augmentation, safe or unsafe: A case series of severe complications of fillers. *J Res Med Sci.* 2011;16:1627-31.
2. Sachdev M, Anantheswar Y, Ashok B, et al. Facial granulomas secondary to injection of semi-permanent cosmetic dermal filler containing acrylic hydrogel particles. *J Cutan Aesthet Surg.* 2010;3:162-6.
3. Haneke E. Managing Complications of Fillers: Rare and Not-So-Rare. *J Cutan Aesthet Surg.* 2015;8:198-210.
4. Wilson E, Rapues J, Jin H, et al. The use and correlates of illicit silicone or "fillers" in a population-based sample of transwomen, San Francisco, 2013. *J Sex Med.* 2014;11:1717-24.
5. Carlos-Fabuel L, Marzal-Gamarra C, Marti-Alamo S, et al. Foreign body granulomatous reactions to cosmetic fillers. *J Clin Exp Dent.* 2012;4:e244-7.
6. De Boule K, Heydenrych I. Patient factors influencing dermal filler complications: prevention, assessment, and treatment. *Clin Cosmet Investig Dermatol.* 2015;8:205-14.